

REVIEW ARTICLE

Mast cell contribution to tumor angiogenesis: a clinical approach

Enrico Crivellato¹, Beatrice Nico², Domenico Ribatti²

¹ Department of Medical and Morphological Research, Anatomy Section, University of Udine Medical School, Udine, Italy

² Department of Human Anatomy and Histology, University of Bari Medical School, Bari, Italy

Correspondence: Prof. E. Crivellato, Department of Medical and Morphological Research, Anatomy section, P.le Kolbe, 3, 33100 Udine, Italy
<enrico.crivellato@uniud.it>

Accepted for publication June 12, 2009

ABSTRACT. Mast cells (MCs) are tissue leukocytes that are distributed throughout the major organs of the body. They are an important local source of preformed and newly synthesized angiogenic molecules. MCs have been linked both to inflammatory and tumor angiogenesis. Indeed, numerous solid tumors and hematological malignancies present MC-rich infiltrates, which are believed to contribute to the formation of a new vascular supply. In addition, angiogenesis and MC density have been shown to increase simultaneously with the pathological progression in many of such tumors. This review will focus on the angiogenic potential of MCs in human solid and hematological tumors.

Keywords: mast cells, tumor angiogenesis

Mast cells (MCs) were first described in 1878 by Paul Ehrlich as metachromatically-staining basophilic cells found in connective tissues [1]. He speculated on the function of these cells and, remarkably, he interpreted MCs as fixed elements implicated in “tissue trophism”, a concept that has recently been rediscovered, MCs being currently regarded as key effector cells in tissue vascularization, remodeling and homeostasis.

MCs may be defined as multi-functional secretory cells that contain numerous toluidine blue- or alcian blue-staining granules in their cytoplasm, expressing high levels of c-kit, the receptor for stem cell factor (SCF), and FcεRI, the high affinity plasma membrane receptor binding IgE antibodies and IgE-antigen complexes. MC secretory granules store a complex mixture of preformed effector molecules – such as biogenic amines, proteoglycans, cytokines and neutral serine proteases – which are released upon appropriate cell stimulation. Accordingly, MCs may be activated through either IgE-dependent or IgE-independent pathways.

MCs have long been implicated in classic IgE-associated allergic disorders such as urticaria, seasonal conjunctivitis, allergic rhinitis and asthma. However, they are now considered to be crucial protagonists in host defence, being first-line responders to different chemical and biological insults in the context of either acquired or innate immune responses. In addition, growing evidence indicates that MCs may have distinct involvement in non-immunological functions, such as angiogenesis, wound healing, tissue remodeling and fibrosis, thus playing a role in tissue homeostasis.

MCs are also involved in cancer. Indeed, they can be found in many different tumor types, where they represent part of the infiltrating elements that localize to the tumor stroma. It was Paul Ehrlich who, besides discovering MCs, first observed that MCs often crowded around tumor masses [1]. Interestingly, MCs have apparently been associated with either resistance or susceptibility to tumor growth. MCs indeed accumulate in the stroma surrounding certain tumors and the molecules they secrete can benefit the tumor. By contrast, MC numbers can also increase at the site of tumor growth and participate in tumor rejection. A major point linking MCs to cancer is their well-recognized capacity to synthesize and release potent angiogenic cytokines. Formation of new blood vessels around and inside the tumor mass represents, in turn, a crucial step in the natural history of tumor growth. This review article will first consider the angiogenic potential of MCs, taking into account the complex array of MC products that exert important stimulating effects on blood vessel proliferation. Secondly, it will focus on the complex biology of tumor vasculature. Thirdly, the angiogenic contribution of MCs, in the context of the inflammatory infiltrate that surrounds neoplastic cells and the different clinical outcome that results from the participation of MC in tumor infiltration, will be discussed.

BIOLOGY OF MAST CELLS

MCs are long-lived, ubiquitous cells that are dispersed throughout almost all of the major organs of the body. They can be found particularly in association with

connective tissue structures such as blood vessels, lymphatic vessels and nerves, and in proximity to surfaces that interface the external environment such as those of the respiratory, genitourinary and gastrointestinal system and the skin. MCs are bone marrow-derived elements that originate from hematopoietic stem cells [2]. Committed progenitors, circulating as mononuclear agranular cells, traverse the vascular space and complete their maturation after moving into the different peripheral tissues. Here, they acquire their final phenotypic differentiation under the influence of local tissue microenvironmental factors, which exert critical effects, in particular on the MC protease profile [3]. One of these crucial factors is the c-kit ligand (SCF) secreted by fibroblasts, stromal cells and endothelial cells. A bipotent MC and basophil progenitor has been found in the mouse spleen, although this has not yet been traced back to the bone marrow [4].

Human MCs, as well as mouse MCs, may be classified into one of two types depending on the expression of different proteases in their granules [5]. MC_T cells, also regarded as “immune cell-associated”, contain tryptase and are predominantly located in the respiratory and intestinal mucosa, where they co-localize around T lymphocytes. MC_{Tc} cells contain both tryptase and chymase, along with other proteases such as carboxypeptidase A and cathepsin G. They are predominantly found in connective tissue areas, such as skin, submucosa of stomach and intestine, breast parenchyma, myocardium, lymph nodes, conjunctiva and synovium. A third type of MC, the MC_c cell has also been identified: this MC expresses chymase without tryptase and resides mainly in the submucosa and mucosa of the stomach, small intestinal submucosa and colonic mucosa [6].

MCs have the potential to secrete a wide variety of biologically active products upon exposure to many different immunological and non-immunological stimuli. These mediators are classified as: 1) preformed mediators that are stored in the cytoplasmic granules; 2) *de novo* synthesized lipid mediators, *e.g.*, metabolites of arachidonic acid via either cyclooxygenase (*e.g.*, PGD₂) or lipoxygenase (*e.g.*, LTC₄) pathways; 3) a large number of cytokines, chemokines and growth factors [7]. Preformed mediators stored in the secretory granules can be released by two, morphologically distinct secretory pathways, referred to as exocytosis (also called “anaphylactic degranulation”), and piecemeal degranulation.

ROLE OF MAST CELLS IN INFLAMMATORY CONDITIONS

Not only do MCs display critical effector functions in type I, IgE-associated allergic disorders, but they also participate in host defence against parasites, bacteria, viruses and fungi. Indeed, MCs release a multitude of biologically potent mediators, which exert proinflammatory or immunoregulatory functions, and express a wide spectrum of surface receptors for cytokines, chemokines, immunoglobulins, complement and bacterial products [8]. This enables MCs to exert crucial functions in the context of either acquired or innate immune responses.

It is now clear that MCs are involved in a variety of pathological contexts, including autoimmunity [9]. Interestingly, MCs have been shown to express either beneficial or detrimental effects in a number of essential biological functions [10]. MCs, for instance, have a crucial, life-saving role in experimental bacterial infections. Using genetically MC-deficient W/W^V mice, it has been shown that MCs exert a fundamental protective role in a model of acute septic peritonitis following caecum ligation and puncture, and in a model of enterobacteria inocula [11, 12]. This protective effect is mainly due to the release of tumor necrosis factor (TNF)- α , but other MC-derived products, such as cathelicidins, chymase and leukotrienes, may exert direct bactericidal activity or degrade toxic peptides [13]. Thus, MCs may behave as vital sentinels that orchestrate potent inflammatory reactions against different microorganisms, linking the innate immunity with the adaptive immune system. On the other hand, they play a critical role in initiating or worsening diseases such as rheumatoid arthritis, multiple sclerosis, bullous pemphigoid and atherosclerosis [14]. In addition, growing evidence suggests that MCs exert distinct, non-immunological functions, playing a relevant role in tissue homeostasis, remodeling and fibrosis, as well as in the processes of tissue angiogenesis.

MAST CELL-DERIVED SECRETORY PRODUCTS

The function of MCs is related to their capacity to release huge amounts of biologically active products upon appropriate stimulation. MCs release low molecular weight substances, such as histamine, as well as cytokines and chemokines that exert profound effects on inflammation and cancer [7]. Electron microscopy has provided ultrastructural evidence that preformed mediators stored in MC secretory granules can be released by two distinct secretory pathways, referred to as exocytosis (also called “anaphylactic degranulation”) and piecemeal degranulation [15, 16]. Exocytosis is an “all-or-nothing” event, which consists of a rapid and massive secretory process that occurs during IgE-dependent hypersensitivity reactions. In exocytosis, the membranes of cytoplasmic granule fuse with each other and with the plasma membrane, causing the formation of open secretory channels that allow the discharge of granule constituents into the local extracellular environment. Piecemeal degranulation, conversely, represents a particulate mode of MC secretion, which is characterized by a mechanism of a slow and “little by little” release of granule contents that occurs without membrane fusion or granule opening to the cell exterior. Remarkably, piecemeal degranulation represents the most frequently observed pattern of MC secretion [15]. It has been particularly detected in MCs infiltrating areas of chronic inflammation or tumors. During piecemeal degranulation, MCs are believed to differently and selectively release distinct granule components [17].

During the immediate hypersensitivity reaction, MCs undergo a sequence of releasing events [14]. Exposure to specific multivalent antigens results in the bridging

of IgE molecules bound to FcεRI on the MC surface. This event causes a rapid discharge of preformed, vasoactive, proinflammatory and nociceptive mediators from secretory granules, as well as the release of newly-formed mediators. The cross-linking of surface-bound IgE by antigen leads to the rapid release of histamine, specific proteases, vascular endothelial growth factor (VEGF) and TNF-α from rich, intracellular stores. On activation, MCs also rapidly synthesize bioactive metabolites of arachidonic acid, prostaglandins and leukotrienes. In addition, MC activation leads to the *de novo* synthesis of several cytokines, such as interleukin (IL)-3, IL-4, IL-5, IL-6, IL-10, IL-13, IL-14, nerve growth factor (NGF), and different chemokines, such as macrophage inflammatory protein (MIP)-1α, monocyte chemoattractant protein (MCP)-1 and lymphotactin. Remarkably, the types of cytokines produced are not fixed but depend upon the type of MC stimulation. Thus, the response of MCs is flexible.

THE PROCESS OF ANGIOGENESIS

The term angiogenesis refers to the formation of new blood vessels from pre-existing vascular structures, *i.e.* capillaries and post-capillary venules [18]. Angiogenesis first occurs during embryonic development and represents a key factor for tissue and organ expansion. Particularly in the later stages of embryo development, the vascularization of many tissues – such as the yolk sac, kidney, thymus, brain, limb and choroid plexus – occurs by angiogenesis. Angiogenesis is a complex process that involves a highly orchestrated series of molecular and cell events, which are under the control of different genetic and epigenetic mechanisms [19]. Angiogenesis may be considered as at least two types according to the different morphological pattern: (a) the so-called “sprouting” angiogenesis, which is characterized by the proliferation and migration of endothelial cells into avascular sites; (b) “non-sprouting” angiogenesis or intussusceptive microvascular growth, which occurs by splitting of the existing vasculature by transluminal pillars or transendothelial bridges [18, 20]. Angiogenesis also occurs during adult life. In such instance, it accompanies the course of various important physiological and pathophysiological conditions, such as ovulation, endometrial vascularization in the menstrual cycle and pregnancy, and wound healing.

There is general consensus that angiogenesis occurs during inflammation and tumor progression. Increasing evidence indicates that angiogenesis is a key accompanying event in the development of inflammatory reactions and in the pathophysiology of tissue remodeling during allergic disorders [21]. In tumor areas, angiogenesis creates a new vascular supply that conveys oxygen and nutrients to the rapidly proliferating tissue and removes the by-products of cellular metabolism.

Numerous fixed and inflammatory cells can produce and release angiogenic growth factors. Molecules that favour new vessel formation can also be secreted by tumor cells [22]. The process of angiogenesis depends on the balance of the positive and negative angiogenic mediators within

the vascular microenvironment and requires the functional activities of a number of molecules, including angiogenic factors, extracellular matrix proteins, adhesion receptors, and proteolytic enzymes [18]. Thus, vascular development in a given tissue is controlled in a remarkably complex way by many microenvironmental factors. Among these, increasing attention has recently been devoted to inflammatory cells. Inflammatory cells indeed regulate endothelial cell functions related to physiological angiogenesis as well as inflammatory and tumor-associated angiogenesis.

THE PROCESS OF TUMOR ANGIOGENESIS

Angiogenesis is a critical process in tumor progression because the vascular network produced by the host is essential to allow neoplastic cell populations to form a clinically observable tumor [23, 24]. In addition, new blood vessels provide the neoplastic cells with a gateway through which they may enter the circulation and metastasize to distant sites. Indeed, the special structure of tumor blood vessels, with their often incomplete endothelial envelope and their increased permeability, favours escape of neoplastic cells and generation of metastases. Both solid and hematological tumors are endowed with angiogenic capability and their growth, invasion and metastasis are angiogenesis-dependent [23, 25]. Thus the “angiogenic switch” – the passage from the preangiogenic phenotype to the angiogenic phenotype – is indispensable for tumor growth and metastatic dissemination because it allows the formation of a tumor neovasculature [26, 27]. The different components of the tumor “microenvironment” play a crucial role in regulating tumor growth. The extracellular matrix, the stromal cells localized in the tumor domain, the microvessels and angiogenic factors released by a cohort of cell types, and the inflammatory cells surrounding and infiltrating the tumor mass, all participate in the tumor evolution. Such a microenvironment is a complex system influenced by many cell types, including endothelial cells and their precursors, pericytes, smooth-muscle cells, fibroblasts, neutrophils, eosinophils, basophils, MCs, T, B and natural killer lymphocytes, and antigen-presenting cells, such as macrophages and dendritic cells, which communicate through a complex network of intercellular signaling pathways that are mediated by surface adhesion molecules, cytokines and their receptors. In particular, tumor angiogenesis results not only from the interaction of cancer cells with endothelial cells. Surrounding inflammatory cells also have a crucial role in directing the neoformation of blood vessels.

Remarkably, tumor blood vessels display many structural defects that explain the functional abnormality of this kind of blood vasculature. They are irregular in size, shape and branching pattern, they lack the normal vessel hierarchy and do not display the recognizable features of arterioles, capillaries and venules [28]. Tumor-associated endothelial cells form a structurally defective endothelium, which shows discontinuities or gaps that allow hemorrhage, and facilitate permeability of macromolecules and the traffic of

tumor cells into the bloodstream. They are disorganized, irregularly shaped, overlap one another, have luminal projections and give rise to abluminal sprouts. The basement membrane that envelops endothelial cells and pericytes of tumor vessels may have extra layers that have no apparent association with the cells. Pericytes of tumor vessels are loosely associated with endothelial cells, have abnormal shape, paradoxically extend cytoplasmic processes away from the vessel wall, and have extra layers of loosely fitting basement membrane. Thus, tumor vasculature is typically aberrant and disordered. For this reason tumor vasculature does not form an effective barrier, allowing for microvascular leakiness and tumor cell escape.

MAST CELLS AND ANGIOGENESIS

MCs are an abundant source of angiogenic factors [29]. Under physiological conditions, MCs are particularly prominent in the close vicinity of capillaries and lymphatic channels. In many inflammatory disorders characterized by a profound vascular remodeling, the infiltrate exhibits numerous MCs that show the structural features of degranulating elements. In various tumor models, MCs appear at the edges of invasive tumors, where they facilitate angiogenesis by releasing preformed mediators or by triggering proteolytic release of extracellular matrix-bound angiogenic compounds. Human, rat and mouse MCs release preformed fibroblast growth factor (FGF)-2 from their secretory granules [30, 31]. Human cord blood-derived MCs release VEGF upon stimulation through Fc ϵ RI and c-kit. Both FGF-2 and VEGF have also been identified by immunohistochemistry in mature MCs in human tissues [30, 32, 33]. It has recently been shown that human MCs are a potent source of VEGF in the absence of degranulation, through activation of the EP(2) receptor by prostaglandin E₂ [34]. Selective release of VEGF by human MCs is regulated by corticotrophin-releasing hormone [35]. It has also been demonstrated that rat peritoneal MCs contain angiogenic factors stored in their secretory granules [36]. Granulated MCs and their granules, but not degranulated mast cells, are able indeed, to stimulate an intense angiogenic reaction in the chick embryo chorioallantoic membrane (CAM) assay. This angiogenic activity is partly inhibited by anti-FGF-2 and -VEGF antibodies, suggesting that these cytokines are involved in the angiogenic reaction. Similarly, it has been demonstrated, using the rat mesenteric-window angiogenic assay, that intraperitoneal injection of compound 48/80 – a potent MC secretagogue – causes a vigorous angiogenic response [37]. The same treatment in mice also causes angiogenesis [38].

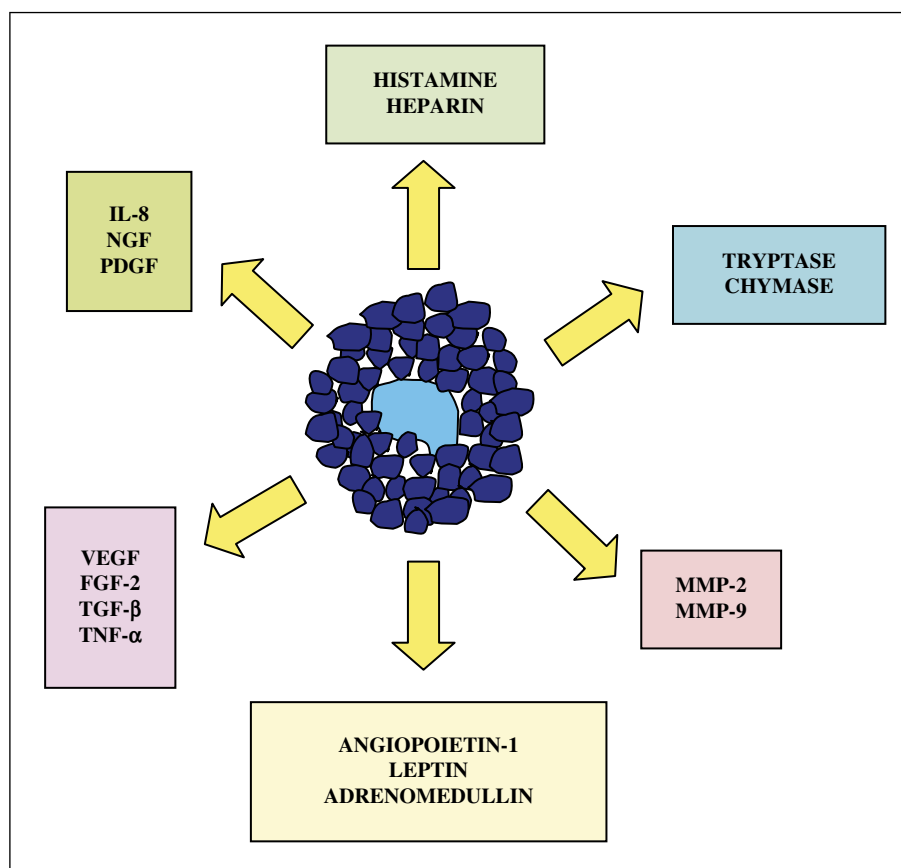
MCs store large amounts of preformed, active serine proteases, such as tryptase and chymase, in their secretory granules [39]. A role in angiogenesis for the proteolytic enzymes tryptase and chymase has been established. Tryptase, in particular, stimulates the proliferation of human vascular endothelial cells, promotes vascular tube formation in culture and also degrades connective tissue matrix to provide space for neovascular growth. Tryptase also acts indirectly by activating latent matrix

metalloproteinases (MMPs) and plasminogen activator (PA), which, in turn, degrade the extracellular connective tissue with consequent release of VEGF or FGF-2 from their matrix-bound state [40]. MC-derived chymase degrades extracellular matrix components and therefore matrix-bound VEGF could be potentially released. In a hamster sponge implant model, chymase promotes angiogenesis through generating angiotensin II from angiotensin I [41]. Chymase also activates ProMMP-9 to generate MMP-9, also known as gelatinase B, which is a matrix metalloproteinase involved in angiogenesis, stromal remodeling and tumor cell invasion. MCs also have the potential to synthesize and release MMP-9 [42]. Other MC-specific mediators with angiogenic properties include histamine and heparin. Both molecules have been shown to stimulate proliferation of endothelial cells and to induce the formation of new blood vessels in the CAM-assay [43, 44]. Histamine, the major preformed mediator, stimulates new vessel formation by acting through both H₁ and H₂ receptors [44]. Heparin, the main glycosaminoglycan constituent of MC granules, may act directly on blood vessels or indirectly by inducing release of FGF-2 from the extracellular storage site. In addition, other cytokines produced by MCs, such as TNF- α , TGF- β , NGF [45] and IL-8, have been implicated in normal and tumor-associated angiogenesis [40]. Recently, MCs from human uterine leiomyomas have been found to contain leptin, a 167-amino-acid residue peptide mainly secreted by adipocytes which, in addition to its involvement in obesity development, has also been found to express angiogenic activity [46, 47]. Endothelial cells might exert maintenance functions on MCs since it is known that human dermal endothelial cells express the MC growth and chemotactic factor SCF [48]. Furthermore, SCF may induce urokinase-type plasminogen-activator-receptor (uPAR)-expression in MCs, and cells stimulated in this way could also respond chemotactically to uPA released by endothelial cells [49]. Several factors released by tumor cells, such as SCF and adrenomedullin, are thought to be responsible for the recruitment of MCs into tumors [50, 51]. MCs also express a number of chemokine receptors, including CXCR4, CCR3 and CCR5, the ligands that are upregulated by various cell types in most forms of tumors [52]. An inventory of MC-derived angiogenic mediators is depicted in *figure 1*.

MAST CELLS AND ANGIOGENESIS IN HUMAN PATHOLOGY

Solid tumors

Extensive clinical investigations suggest that MCs are key host cells in the tumor infiltrate, with important consequence for tumor cell fate. In general terms, MC density correlates with angiogenesis and poor tumor outcome. In some studies however, increased MC numbers have been found either to correlate with improved clinical survival or not to correlate with survival at all. We have already seen that MCs synthesize and release a vast array of proinflammatory and angiogenic molecules that favour new vessel formation, either directly or *via*

**Figure 1**

Schematic drawing illustrating the most active angiogenic mediators synthesized and secreted by mast cells.

local recruitment of activated inflammatory cells. Accordingly, early laboratory investigations have documented a decreased rate of tumor angiogenesis in MC-deficient W/W^v mice [53]. As to human pathology, an increased number of MCs has been reported in angiogenesis associated with a number of vascular, solid and hematological neoplasms. At present, it is not known if tumor-associated MCs are involved in “sprouting” angiogenesis or in “non-sprouting” angiogenesis, or in both. An association between MCs and new vessel formation has been reported in breast cancer [54, 55]. In malignant breast lesions, the number of MCs with tryptase activity has been found to be significantly higher than in benign lesions. MCs are concentrated at the tumor edge, the so-called “invasion zone” [56]. Breast cancer patients with metastasis in the axillary nodes reveal greater numbers of MCs in all nodes examined compared with patients without metastases [57]. In a study on the sentinel lymph-nodes in breast cancer patients, angiogenesis has been shown to increase with the number of tryptase-positive MCs, and their values were significantly higher in lymph nodes with micrometastasis compared with those without [58]. By contrast, other authors have maintained that the presence of MCs in the peritumoral stroma of breast carcinoma is associated with a favourable prognosis [54, 59, 60].

An association between MCs and angiogenesis has also been reported in colorectal carcinoma. Increased accumulation of toluidine blue- or tryptase-positive MCs infiltrating colorectal carcinoma has been shown to correlate

with increased microvessel density and a less favorable prognosis [61, 62]. Patients with low MC density and hypovascular tumor tissues had significantly longer survival than those with high MC density and hypervascular tumor biopsies.

Again, an association between MCs and new vessel formation has been documented in cervical carcinoma. Indeed, tryptase-positive MCs increase in number, and vascularization increases in a linear fashion, from dysplasia to invasive cancer of the uterine cervix [63]. In another study, the total number of MCs has been shown to remain constant through the different stages of malignant transformation (cervical intraepithelial neoplasia grade 1-3), but a significant increase in the invasive carcinoma group was observed, this increase being mainly due to the MCt phenotype [64]. Recently, angiogenesis has been shown to correlate with the tryptase-positive MC count in human endometrial cancer. Both parameters were found to increase in agreement with tumor progression [65]. In this type of tumor, the extent of angiogenesis has been shown to correlate with expression of MMP-2 and MMP-9, both metalloproteinases being potentially secreted by infiltrating MCs [66]. In uterine leiomyomas, the number of tryptase- and leptin-positive MCs was also seen to correlate with vascular density [67]. In this type of uterine tumor, the predominant subset of infiltrating MCs was the MCt type, possibly recruited by the CCL5 and CCL11 chemokines secreted by the smooth muscle tumor cells [68]. Angiomyofibroblastoma in the vaginal wall is a rare, highly vascularized tumor.

Immunohistochemical analysis of VEGF-positive cells in a case of this tumor indicated that MCs and not tumor cells express this angiogenic cytokine, implying that MCs may play a crucial role in angiogenesis in angiomatofibrosarcoma [69]. An association between VEGF and MCs with angiogenesis has been demonstrated in laryngeal carcinoma [70] and in small lung carcinoma [71, 72]. In lung adenocarcinoma, chymase-positive MCs accumulate in the neoplastic lesion. A significant correlation has been found between chymase-positive MC counts and microvessel counts in Noguchi type-C tumors (localized bronchioloalveolar carcinoma with active fibroblastic proliferation) [73]. In a similar way, significant correlations were observed not only between MTC and microvessel count, but also between MCTC and microvessel count in the border region of stage I non-small cell lung cancer [74]. In the central region, a significant correlation between MCTC and the number of microvessels was observed, but there was no significant correlation between MCT and the microvessel count. This study demonstrates that MCs tend to aggregate with higher density in the border region of non-small cell lung carcinomas where microvessel density is also much higher than in the central region. Conversely, according to another study, the number of MCs (along with macrophages and eosinophil leukocytes) did not correlate with angiogenesis and tumor stage in non-small cell lung carcinomas [75]. The number of total MCs and chymase-positive MCs also correlates with microvessel counts in gastric carcinoma, and both parameters are associated with a poorer clinical prognosis, suggesting that MCs may contribute to tumor growth and progression [76, 77]. A significantly increased number of MCs (and macrophages) has been found in pancreatic ductal adenocarcinoma in comparison with normal pancreas, the number of MCs directly correlating with the presence of lymph node metastases [78]. MCs were found to express VEGF-A, VEGF-C and FGF-2. Tumors with higher microvessel density had higher number of infiltrating MCs (and macrophages), suggesting that MCs may influence the metastatic capacity of the cancer cells and may contribute to the development of tumors with high angiogenic activity. In a similar way, the number of MCs was found to be significantly increased in hepatocellular carcinoma, with higher values in poorly differentiated versus well differentiated specimens [79]. MC count correlated with the number of microvessels.

In renal cell carcinomas, MCs were found to be significantly increased both in the tumor mass and surrounding areas. Increased MC density significantly correlated with microvessel density, suggesting that MC infiltration may contribute to tumor angiogenesis and acceleration of tumor growth possibly through secretion of VEGF and MMP-9 [80]. In one study however, higher numbers of MCs in tumors of the kidney correlated positively with increased microvessel density, but this correlation did not translate to patient survival [81].

An association between MCs and angiogenesis has also been reported in skin and oral tumors [82]. MC accumulation has been noted repeatedly around melanomas, especially invasive melanoma [83-85]. MC accumulation was correlated with increased neovascularization, MC

expression of VEGF [86] and FGF-2 [87], tumor aggressiveness and poor prognosis. Indeed, a prognostic significance has been attributed to MCs and microvascular density not only in melanoma [88], but also in squamous cell cancer of the oesophagus [89]. In oral squamous cell carcinoma, the density of MCs and microvessels appears to increase with disease progression [90]. Indeed, MC and microvessel counts are significantly higher in oral squamous cell carcinoma than in hyperkeratosis and normal oral mucosa.

In human pterygium, a benign and highly vascularized tumor of the conjunctiva soft tissue, the number of tryptase-positive infiltrating MCs was found to be significantly increased in comparison to MC values in normal conjunctiva, and to correlate with microvessel count [91]. This suggests that the characteristic neovascularization observed in pterygium may be sustained, at least in part, by MC angiogenic mediators, in particular tryptase.

Hematological malignancies

The role of angiogenesis in the growth and progression of cancers of hematopoietic lineage is also well established [92]. Indeed, tumors such as B-cell non-Hodgkin's lymphomas (B-NHL), lymphoblastic leukaemia, B-cell chronic lymphocytic leukaemia, acute myeloid leukaemia and multiple myeloma are clearly related in their progression to the degree of angiogenesis [93]. In general terms, MC density, bone marrow microvessel count and clinical prognosis have been found to correlate in hematological malignancies. Bone marrow angiogenesis, evaluated as microvessel area, and MC counts are highly correlated in patients with non-active and active multiple myeloma and in those with monoclonal gammopathies of undetermined significance (MGUS). In addition, both parameters increase simultaneously in active multiple myeloma [94-97]. These data tentatively suggest that an increasing number of MCs may be recruited and activated by more malignant plasma cells in active multiple myeloma, and that angiogenesis in this disease phase may be mediated, at least in part, by angiogenic factors contained in their secretory granules [24, 98].

Angiogenesis is involved in the pathogenesis of B-cell chronic lymphocytic leukaemia (CLL). Indeed, low cellular levels and high serum concentrations of VEGF, as well as the extent of bone marrow angiogenesis, correlate closely with the outcome of the disease [99]. Remarkably, tryptase-positive MCs are increased in the bone marrow of patients with B-cell CLL and their density reflects bone marrow angiogenesis [100]. In addition, there is also a correlation with disease progression, thus tryptase-positive MCs predict clinical outcome in patients with early B-cell chronic lymphocytic leukaemia [101].

A similar pattern of correlation between bone marrow microvessel count, total and tryptase-positive MC density, and tumor worsening has been found in patients with myelodysplastic syndromes [102]. Data suggest that angiogenesis in myelodysplastic syndromes increases with their progression and that MCs may inter-

vene in the angiogenic response in these syndromes through tryptase contained in their secretory granules.

A striking association between MCs and microvessel counts has been found also in benign lymphadenopathies and B-NHL, and both parameters have been shown to increase as a function of tumor progression, as defined by its increasing malignancies grades [103, 104]. In B-NHL and multiple myeloma, MCs rest near or around blood or lymphatic capillaries. Interestingly, electron microscopic examination of lymph node and bone marrow MCs in B-NHL and multiple myeloma patients show ultrastructural features of slow and particulate secretion as it occurs in piecemeal degranulation [16, 94, 104, 105]. This ultrastructural appearance may reflect slow and progressive release of angiogenic factors by infiltrating MCs, favouring chronic and progressive stimulation of MC degranulation [106].

Besides stimulating angiogenesis in the bone marrow of multiple myeloma patients, MCs have the property of contributing to vasculogenic mimicry [107]. Indeed, electron and confocal microscopy studies have demonstrated that in the bone marrow of patients with multiple myeloma, typical tryptase-positive MCs interact physically with the endothelial cells lining the vascular lumina, perhaps as a result of dysregulated vasculogenic development. This evidence highlights the importance of the stromal microenvironment during angiogenesis in the pathophysiology of multiple myeloma, and provides a novel perspective into the complex interplay between stromal and vascular components in the bone marrow microenvironment involved in the induction of hypervascularization in multiple myeloma.

CONCLUSION

Despite numerous studies suggest a correlation between MC density, angiogenesis and tumor progression, there is still controversy over the role of MCs and MC-dependent angiogenesis in the development of tumors. The divergence of opinion on the functional role of MCs as effector cells in tumor angiogenesis is not surprising given MC versatility and the plentiful mediators these cells release in the tumor microenvironment. As MCs have the potency to express either favourable or detrimental effects on tumor cell growth, the hypothesis has been proposed that this dual role may depend on the way MCs release their bioactive molecules from secretory granules [106]. Frank exocytosis would export secretory cytokines mainly involved in promoting tumor cell apoptosis, whilst piecemeal degranulation, a particulate and possibly selective way of MC secretion, would allow for release of mediators and growth factors principally responsible of angiogenesis, immuno-suppression and extracellular matrix disruption [106].

MCs *per se* may exert inhibiting effects on tumor cell growth through secretion of cytotoxic/apoptotic mediators contained in their cytoplasmic granules, such as IL-4, TNF- α and chymase. The matter is even more complicated because MCs, despite their ability to release so many angiogenic factors, are also known to secrete

antiangiogenic modulators, such as IFN- α , IFN- β , IFN- γ and TGF- β . This puzzling scenario is properly exemplified by the role played by MCs in hemangioma. MCs have been shown to be abundant within hemangioma tissues [108]. However, the number of MCs is highest during the involuting phase, lower in the involuted phase and lowest in the proliferating phase [109]. It has been suggested that one of the functions of MCs in hemangioma is to release factors leading to regression of neovessels. The observation of a significant increase in MC numbers after steroid treatment supports this hypothesis, and indicates that MCs may play antiangiogenic roles and accelerate the involution of hemangioma. Another apparently paradoxical aspect of MC-related angiogenesis in tumors is to be found in advanced ovarian cancer. Surprisingly, patients with high peritumoral MC infiltration and higher microvascular density have a better prognosis than those with low MC or low microvascular densities [110].

In conclusion, the great majority of clinical studies to date support an accessory role for MCs in the development and progression of solid and hematological tumors through their strong angiogenic potential. Further studies are needed to dissect the complex cell and mediator signaling network operating in the tumor microenvironment in order to elucidate the specific contribution of MCs to tumor growth and tumor-related angiogenesis.

REFERENCES

1. Ehrlich P. Beiträge zur Theorie und Praxis der Histologischen Färbung. Thesis, Leipzig University, 1878.
2. Gurish MF, Austen KF. The diverse role of mast cells. *J Exp Med* 2001; 194: 1-5.
3. Levi-Schaffer F, Austen KF, Gravallesse PM, Stevens RL. Coculture of interleukin 3-dependent mouse mast cells with fibroblasts results in a phenotypic change of mast cells. *Proc Natl Acad Sci USA* 1986; 63: 6485-8.
4. Gurish MF, Boyce JA. Mast cells: ontogeny, homing, and recruitment of a unique innate effector cell. *J Allergy Clin Immunol* 2006; 117: 1285-91.
5. Heib V, Becker M, Taube C, Stassen M. Advances in the understanding of mast cell function. *Brit J Haematol* 2008 in press.
6. Irani AM, Schwartz LB. Human mast cell heterogeneity. *Allergy and Asthma Proceedings* 1994; 15: 303-8.
7. Galli SJ, Tsai M. Mast cells: Versatile regulators of inflammation, tissue remodeling, host defence and homeostasis. *J Dermatol Sci* 2008; 49: 7-19.
8. Gilfillan AM, Tkaczyk C. Integrated signalling pathways for mast cell activation. *Nature Review Immunology* 2006; 6: 218-30.
9. Sayed BA, Christy A, Quirion MR, Brown MA. The master switch: the role of mast cells in autoimmunity and tolerance. *Annu Rev Immunol* 2008; 26: 705-39.
10. Metz M, Grimaldeston MA, Nakae S, Piliponsky AM, Tsai M, Galli SJ. Mast cells in promotion and limitation of chronic inflammation. *Immunol Rev* 2007; 217: 304-28.
11. Echtenacher B, Männel DN, Hültner L. Critical protective role of mast cells in a model of acute septic peritonitis. *Nature* 1996; 381: 75-7.

12. Malaviya R, Ikeda T, Ross E, Abraham SN. Mast cell modulation of neutrophil influx and bacterial clearance at sites of infection through TNF- α . *Nature* 1996; 381: 77-80.
13. Metz M, Siebenhaar F, Maurer M. Mast cell functions in the innate skin immune system. *Immunobiology* 2008; 213: 251-60.
14. Benoist C, Mathis D. Mast cells in autoimmune disease. *Nature* 2002; 420: 875-8.
15. Dvorak AM. Basophil and mast cell degranulation and recovery. In: Harris JR, ed. *Blood Cell Biochemistry*. New York: Plenum Press, 1991: 340-77.
16. Crivellato E, Nico B, Vacca A, Dammacco F, Ribatti D. Mast cell heterogeneity in B-cell non-Hodgkin's lymphomas: an ultrastructural study. *Leuk Lymphoma* 2002; 43: 2201-5.
17. Theoharides TC, Kempuraj D, Tagen M, Conti P, Kalogeromitros D. Differential release of mast cell mediators and the pathogenesis of inflammation. *Immunol Rev* 2007; 217: 65-78.
18. Risau W. Mechanisms of angiogenesis. *Nature* 1997; 386: 671-4.
19. Ribatti D. Genetic and epigenetic mechanisms in the early development of the vascular system. *Journal of Anatomy* 2006; 208: 139-52.
20. Burri PH, Djonov D. Intussusceptive angiogenesis – the alternative to capillary sprouting. *Mol Aspects Med* 2002; 23: S1-27.
21. Puxeddu I, Ribatti D, Crivellato E, Levi-Schaffer F. Mast cells and eosinophils: a novel link between inflammation and angiogenesis in allergic diseases. *J Allergy Clin Immunol* 2005; 116: 531-6.
22. Folkman J. Angiogenesis in cancer, vascular rheumatoid and other disease. *Nat Med* 1995; 1: 27-31.
23. Ribatti D, Vacca A, Dammacco F. The role of vascular phase in solid tumor growth: a historical review. *Neoplasia* 1999; 1: 293-302.
24. Vacca A, Ribatti D. Bone marrow angiogenesis in multiple myeloma. *Leukemia* 2006; 20: 193-9.
25. Folkman J. What is the role of endothelial cells in angiogenesis? *Lab Invest* 1984; 51: 601-4.
26. Folkman J, Watson K, Ingber D, Hanahan D. Induction of angiogenesis during the transition from hyperplasia to neoplasia. *Nature* 1989; 339: 58-61.
27. Ribatti D, Nico B, Crivellato E, Roccaro AM, Vacca A. The history of the angiogenic switch concept. *Leukemia* 2007; 21: 44-52.
28. Ribatti D, Nico B, Crivellato E, Vacca A. The structure of the vascular network in tumors. *Cancer Lett* 2007; 248: 18-23.
29. Norrby K. Mast cells and angiogenesis. *APMIS* 2002; 110: 355-71.
30. Qu Z, Liebler JM, Powers MR, *et al.* Mast cells are a major source of basic fibroblast growth factor in chronic inflammation and cutaneous hemangioma. *Am J Pathol* 1995; 147: 564-73.
31. Qu Z, Huang X, Ahmadi P, *et al.* Synthesis of basic fibroblast growth factor by murine mast cells. Regulation by transforming growth factor beta, tumor necrosis factor alpha, and stem cell factor. *Int Arch Allergy Immunol* 1998; 115: 47-54.
32. Qu Z, Kayton RJ, Ahmadi P, *et al.* Ultrastructural immunolocalization of basic fibroblast growth factor in mast cell secretory granules. Morphological evidence for bfgf release through degranulation. *J Histochem Cytochem* 1998; 46: 1119-28.
33. Grutzkau A, Kruger-Krasagakes S, Baumeister H, *et al.* Synthesis, storage, and release of vascular endothelial growth factor/vascular permeability factor (VEGF/VPF) by human mast cells: implications for the biological significance of VEGF 206. *Molecular Biology of the Cell* 1998; 9: 875-84.
34. Abdel-Majid RM, Marshall JS. Prostaglandin E2 induces degranulation-independent production of vascular endothelial growth factor by human mast cells. *J Immunol* 2004; 172: 1227-36.
35. Cao L, Curtis CL, Theoharides TC. Corticotropin-releasing hormone induces vascular endothelial growth factor release from human mast cells via the cAMP/protein kinase A/p38 mitogen activate protein kinase pathway. *Mol Pharmacol* 2006; 69: 998-1006.
36. Ribatti D, Crivellato E, Candussio L, *et al.* Mast cells and their secretory granules are angiogenic in the chick embryo chorioallantoic membrane. *Clin Exp Allergy* 2001; 31: 602-8.
37. Norrby K, Jakobsson A, Sörbo J. Mast cell-mediated angiogenesis: a novel experimental model using the rat mesentery. *Virchows Archiv B* 1986; 52: 195-206.
38. Norrby K, Jakobsson A, Sörbo J. Mast-cell secretion and angiogenesis, a quantitative study in rats and mice. *Virchows Archiv B* 1989; 57: 251-6.
39. Metcalfe DD, Baram D, Mekori YA. Mast cells. *Physiol Rev* 1997; 77: 1033-79.
40. Blair RJ, Meng H, Marchese MJ, Ren S, Schwartz LB, Tonnesen MG. Human mast cells stimulate vascular tube formation: tryptase is a novel potent angiogenic factor. *J Clin Invest* 1997; 99: 2691-700.
41. Muramatsu M, Katada J, Hayashi I, Majima M. Chymase as a proangiogenic factor. A possible involvement of chymase-angiotensin-dependent pathway in hamster sponge angiogenesis model. *J Biol Chem* 2000; 275: 5545-52.
42. Kanbe N, Tanaka A, Kanbe M, Itakura A, Kurosawa M, Matsuda H. Human mast cells produce matrix metalloproteinase 9. *Eur J Immunol* 1999; 29: 2645-9.
43. Ribatti D, Roncali L, Nico B, Bertossi M. Effects of exogenous heparin on the vasculogenesis of the chorioallantoic membrane. *Acta Anat (Basel)* 1987; 130: 257-63.
44. Sörbo J, Jakobson A, Norrby K. Mast cell histamine is angiogenic through receptors for histamine 1 and histamine 2. *Int J Exp Pathol* 1994; 75: 43-50.
45. Cantarella G, Lempereur L, Presta M, *et al.* Nerve growth factor-endothelial cell interaction leads to angiogenesis *in vitro* and *in vivo*. *FASEB Journal* 2002; 16: 1307-9.
46. Ribatti D, Nico B, Belloni AS, Vacca A, Roncali L, Nussdorfer GG. Angiogenic activity of leptin in the chick embryo chorioallantoic membrane is in part mediated by endogenous fibroblast growth factor-2. *Int J Mol Med* 2001; 8: 265-8.
47. Sierra-Honigsmann MR, Nath AK, Murakami C, *et al.* Biological action of leptin as an angiogenic factor. *Science* 1998; 281: 1683-6.
48. Meininger CJ, Brightman SE, Kelly KA, Zetter BR. Increased stem cell factor release by hemangioma-derived endothelial cells. *Lab Invest* 1995; 72: 48-52.
49. Sillaber C, Baghestanian M, Hofbauer R, *et al.* Molecular and functional characterization of the urokinase receptor on human mast cells. *J Biol Chem* 1997; 272: 7824-32.
50. Meininger CJ, Yano H, Rottapel R, Bernstein A, Zsebo KM, Zetter BR. The c-kit receptor ligand functions as a mast cell chemoattractant. *Blood* 1992; 79: 58-963.
51. Zudaire E, Martinez A, Garayoa M, *et al.* Adrenomedullin is a cross-talk molecule that regulates tumor and mast cell function during human carcinogenesis. *Am J Pathol* 2006; 168: 280-91.
52. Juremalm M, Nilsson G. Chemokine receptor expression by mast cells. *Chemical Immunology and Allergy* 2005; 87: 130-44.

53. Starkey JR, Crowle PK, Taubenberger S. Mast cell-deficient W/W^v mice exhibit a decreased rate of tumor angiogenesis. *Int J Cancer* 1988; 42: 48-52.
54. Hartveit F. Mast cells and metachromasia in human breast cancer; their occurrence, significance and consequence; a preliminary report. *J Pathol* 1981; 134: 7-11.
55. Bowrey P, King J, Magarey C, *et al*. Histamine, mast cells and tumour cell proliferation in breast cancer: does preoperative cimetidine administration have an effect? *Brit J Cancer* 2000; 82: 167-70.
56. Kankkunen JP, Harvima IT, Naukkarinen A. Quantitative analysis of tryptase and chymase containing mast cells in benign and malignant breast lesions. *Int J Cancer* 1997; 72: 385-8.
57. Thorensen S, Tangen M, Hartveit F. Mast cells in the axillary nodes of breast cancer patients. *Diagnostic Histopathology* 1982; 5: 65-7.
58. Ribatti D, Finato N, Crivellato E, *et al*. Angiogenesis and mast cells in human breast cancer sentinel lymph nodes with and without micrometastasis. *Histopathology* 2007; 51: 837-42.
59. Aaltomaa S, Lipponen P, Papinaho S, Kosma VM. Mast cells in breast cancer. *Anticancer Res* 1993; 13: 785-8.
60. Dabiri S, Huntsman D, Makretsov N, *et al*. The presence of stromal mast cells identifies a subset of invasive breast cancers with a favourable prognosis. *Mod Pathol* 2004; 17: 690-5.
61. Acikalin MF, Oner U, Topcu I, Yasar B, Kiper H, Colak E. Tumour angiogenesis and mast cell density in the prognostic assessment of colorectal carcinomas. *Dig Liver Dis* 2005; 37: 162-9.
62. Gulubova M, Vlaykova T. Prognostic significance of mast cell number and microvascular density for the survival of patients with primary colorectal cancer. *J Gastroenterol Hepatol* 2009; 24: 1265-75.
63. Benitez-Briebesca L, Wong A, Utrera D, Castellanos E. The role of mast cell tryptase in neoangiogenesis of premalignant and malignant lesions of the uterine cervix. *J Histochem Cytochem* 2001; 49: 1061-2.
64. Cabanillas-Saez A, Schalper JA, Nicovani SM, Rudolph MI. Characterization of mast cells according to their content of tryptase and chymase in normal and neoplastic human uterine cervix. *Int J Gynecol Cancer* 2002; 12: 92-8.
65. Ribatti D, Finato N, Crivellato E, *et al*. Neovascularization and mast cells with tryptase activity increase simultaneously with pathological progression in human endometrial cancer. *Am J Obstet Gynecol* 2005; 193: 1961-5.
66. Iurlaro M, Loverro G, Vacca A, *et al*. Angiogenesis extent and expression of matrix metalloproteinases-2 and -9 correlate with upgrading and myometrial invasion in endometrial carcinoma. *Eur J Clin Invest* 1999; 22: 793-801.
67. Ribatti D, Belloni AS, Nico B, *et al*. Tryptase- and leptin-positive mast cells correlate with vascular density in uterine leiomyomas. *Am J Obstet Gynecol* 2007; 196: 470-7.
68. Zhu XQ, Lv JQ, Lin Y, Xiang M, Gao BH, Shi YF. Expression of chemokines CCL5 and CCL11 by smooth muscle tumor cells of the uterus and its possible role in the recruitment of mast cells. *Gynecol Oncol* 2007; 105: 650-6.
69. Kumasaka T, Mitani K, Shiotsu H, Kato H, Joho M, Suda K. Vascular endothelial growth factor expressed by mast cells rather than tumour cells in angiomyofibroblastoma of the vascular wall. *Histopathology* 2007; 51: 557-9.
70. Sawatsubashi M, Yamada T, Fukushima N, Mizokami H, Tokunaga O, Shin T. Association of vascular endothelial growth factor and mast cells with angiogenesis in laryngeal squamous cell carcinoma. *Virchows Archiv B* 2000; 436: 243-8.
71. Takanami I, Takeuchi K, Narume M. Mast cell density is associated with angiogenesis and poor prognosis in pulmonary adenocarcinoma. *Cancer* 2000; 88: 2686-92.
72. Tomita M, Matsuzaki Y, Onitsuka T. Effect of mast cells on tumor angiogenesis in lung cancer. *Ann Thorac Surg* 2000; 69: 1686-9.
73. Nagata M, Shijubo N, Walls AF, Ichimiya S, Abe S, Sato N. Chymase-positive mast cells in small sized adenocarcinoma of the lung. *Virchows Archiv* 2003; 443: 565-73.
74. Ibaraki T, Muramatsu M, Takai S, *et al*. The relationship of tryptase- and chymase-positive mast cells to angiogenesis in stage I non-small cell lung cancer. *Eur J Cardiothorac Surg* 2005; 28: 617-21.
75. Tataroglu C, Kargi A, Özkul S, Esrefoglu N, Akkoclu A. Association of macrophages, mast cells and eosinophil leukocytes with angiogenesis and tumor stage in non-small cell lung carcinomas (NSCLC). *Lung Cancer* 2004; 43: 47-54.
76. Yano H, Kinuta M, Tateishi H, *et al*. Mast cell infiltration around gastric cancer cells correlates with tumor angiogenesis and metastasis. *Gastric Cancer* 1999; 2: 26-32.
77. Kondo K, Muramatsu M, Okamoto Y, *et al*. Expression of chymase-positive cells in gastric cancer and its correlation with the angiogenesis. *J Surg Oncol* 2006; 93: 36-43.
78. Esposito I, Menicagli M, Funel N, *et al*. Inflammatory cells contribute to the generation of an angiogenic phenotype in pancreatic ductal adenocarcinoma. *J Clin Pathol* 2004; 57: 630-6.
79. Peng SH, Deng H, Yang JF, *et al*. Significance and relationship between infiltrating inflammatory cells and tumor angiogenesis in hepatocellular carcinoma tissues. *World J Gastroenterol* 2005; 11: 6521-4.
80. Zhang Y, Wu XH, Cao GH, Li S. Relationship between expression of matrix metalloproteinase-9 (MMP-9) and angiogenesis in renal cell carcinoma. *Ai Zheng* 2004; 23: 326-9.
81. Tuna B, Yorukoglu K, Unlu M, Mungan MU, Kirkali Z. Association of mast cells with microvessel density in renal cell carcinoma. *Eur Urol* 2006; 50: 530-4.
82. Ch'ng S, Wallis RA, Yuan L, Davis PF, Tan ST. Mast cells and cutaneous malignancies. *Mod Pathol* 2006; 19: 149-59.
83. Dvorak AM, Mihm Jr MC, Osage JE, Dvorak HF. Melanoma. An ultrastructural study of the host inflammatory and vascular responses. *J Invest Dermatol* 1980; 75: 388-93.
84. Reed JA, McNutt NS, Bogdany JK, Albino AP. Expression of the mast cell growth factor interleukin-3 in the melanocytic lesions correlates with an increased number of mast cells in the perilesional stroma: implications for melanoma progression. *J Cutan Pathol* 1996; 23: 495-505.
85. Guidolin D, Crivellato E, Nico B, Andreis PG, Nussdorfer GG, Ribatti D. An image analysis of the spatial distribution of perivascular mast cells in human melanoma. *Int J Mol Med* 2006; 17: 981-7.
86. Toth T, Toth-Jakatics R, Jimi S, Takebayashi S, Kawamoto N. Cutaneous malignant melanoma: correlation between neovascularization and peritumoral accumulation of mast cells overexpressing vascular endothelial growth factor. *Hum Pathol* 2000; 31: 955-60.
87. Ribatti D, Vacca A, Ria R, *et al*. Neovascularization, expression of fibroblast growth factor-2, and mast cells with tryptase activity increase simultaneously with pathological progression in human malignant melanoma. *Eur J Cancer* 2003; 39: 666-74.

88. Ribatti D, Ennas MG, Vacca A, *et al.* Tumor vascularity and tryptase-positive mast cells correlate with a poor prognosis in melanoma. *Eur J Clin Invest* 2003; 33: 420-5.
89. Elpek GO, Gelen T, Aksoy NH, *et al.* The prognostic relevance of angiogenesis and mast cells in squamous cell carcinoma of the oesophagus. *J Clin Pathol* 2001; 54: 940-4.
90. Iamaroon A, Pongsirivet S, Jittidecharakas S, Pattanaporn K, Prapayasatok S, Wanachantararak S. Increase of mast cells and tumor angiogenesis in oral squamous cell carcinoma. *J Oral Pathol Med* 2003; 32: 195-9.
91. Ribatti D, Nico B, Maxia C, *et al.* Neovascularization and mast cells with tryptase activity increase simultaneously in human pterygium. *J Cell Mol Med* 2007; 11: 585-9.
92. Bertolini F, Mancuso P, Gobbi A, Pruneri G. The thin red line: angiogenesis in normal and malignant hematopoiesis. *Exp Hematol* 2000; 28: 993-1000.
93. Ribatti D, Vacca A, Nico B, Crivellato E, Roncali L, Dammacco F. The role of mast cells in tumour angiogenesis. *Brit J Haematol* 2001; 115: 514-21.
94. Ribatti D, Vacca A, Nico B, *et al.* Bone marrow angiogenesis and mast cell density increase simultaneously with progression of human multiple myeloma. *Brit J Cancer* 1999; 79: 451-5.
95. Vacca A, Ribatti D, Roncali L, *et al.* Bone marrow angiogenesis and progression in multiple myeloma. *Brit J Haematol* 1994; 87: 503-8.
96. Vacca A, Moretti S, Ribatti D, *et al.* Progression of mycosis fungoides is associated with changes in angiogenesis and expression of the matrix metalloproteinase 2 and 9. *Eur J Cancer* 1997; 33: 1685-92.
97. Vacca A, Ribatti D, Presta M, *et al.* Bone marrow neovascularization, plasma cell angiogenic potential, and matrix metalloproteinase-2 secretion parallel progression of human multiple myeloma. *Blood* 1999; 93: 3064-73.
98. Ribatti D, Nico B, Vacca A. Importance of the bone marrow microenvironment in inducing the angiogenic response in multiple myeloma. *Oncogene* 2006; 25: 4257-66.
99. Molica S, Vacca A, Ribatti D, *et al.* Prognostic value of enhanced bone marrow angiogenesis in early B-cell chronic lymphatic leukemia. *Blood* 2002; 100: 3344-51.
100. Ribatti D, Molica S, Vacca A, *et al.* Tryptase-positive mast cells correlate positively with bone marrow angiogenesis in B-cell chronic lymphocytic leukemia. *Leukemia* 2003; 17: 1428-30.
101. Molica S, Vacca A, Crivellato E, Cuneo A, Ribatti D. Tryptase-positive mast cells predict clinical outcome of patients with B-cell chronic lymphocytic leukemia. *Eur J Haematol* 2003; 71: 137-9.
102. Ribatti D, Polimero G, Vacca A, *et al.* Correlation of bone marrow angiogenesis and mast cells with tryptase activity in myelodysplastic syndromes. *Leukemia* 2002; 16: 1680-4.
103. Ribatti D, Nico B, Vacca A, *et al.* Do mast cells help to induce angiogenesis in B-cell non-Hodgkin's lymphomas? *Brit J Cancer* 1998; 77: 1900-6.
104. Ribatti D, Vacca A, Marzullo A, *et al.* Angiogenesis and mast cell density with tryptase activity increase simultaneously with pathological progression in B-cell non-Hodgkin's lymphomas. *Int J Cancer* 2000; 85: 171-5.
105. Crivellato E, Nico B, Vacca A, Ribatti D. Ultrastructural analysis of mast cell recovery after secretion by piecemeal degranulation in B-cell non-Hodgkin's lymphoma. *Leuk Lymphoma* 2003; 44: 517-21.
106. Theoharides TC, Conti P. Mast cells: the Jeckyll and Hyde of tumor growth. *Trends Immunol* 2004; 25: 235-41.
107. Nico B, Mangieri D, Crivellato E, Vacca A, Ribatti D. Mast cells contribute to vasculogenic mimicry in multiple myeloma. *Stem Cells Dev* 2008; 17: 19-22.
108. Tan ST, Wallis RA, He Y, Davis PF. Mast cells and hemangioma. *Plast Reconstr Surg* 2004; 113: 999-1011.
109. Sun ZJ, Zhao YF, Zhao JH. Mast cells in hemangioma: a double-edged sword. *Med Hypotheses* 2007; 68: 805-7.
110. Chan JK, Magistris A, Loizzi V, *et al.* Mast cell density, angiogenesis, blood clotting, and prognosis in women with advanced ovarian cancer. *Gynecol Oncol* 2005; 99: 20-5.