

Strategy of treating secundum atrial septal defect not referred to percutaneous closure

Fei Zhang MD, PhD¹ | Yifeng Yang MD, PhD² | Qin Wu MD, PhD² | Wancun Jin MD² | Haisong Bu MD² | Sijie Wu MD² | Tianli Zhao MD, PhD² | Shijun Hu MD, PhD²

¹NanShan people's hospital of ShenZhen, P.R. China

²Department of Cardiovascular Surgery, the Second Xiangya Hospital, Central South University, Changsha, P.R. China

Correspondence

Shijun Hu, Department of Cardiovascular Surgery, The Second Xiangya Hospital, Central South University, 139 Renmin Central Road, Changsha, Hunan 410011, P.R. China.

Email: hushijun@csu.edu.cn

Abstract

Objective: To evaluate safety and effectiveness of intraoperative device closure for secundum atrial septal defect (ASD) not referred to percutaneous closure.

Design and Patients: From April 2010 to December 2018, 231 secundum ASD children (≤ 14 years) directly recommended to surgical repair were enrolled in this study. These patients were divided into two groups according to the parents' choice based on surgeons' recommendation. Follow-up evaluations were adopted at 2 weeks, 3 months, 6 months, and 12 months after the procedure and yearly thereafter. In Group A, 127 patients underwent an initial attempt at device closure. In Group B, 104 patients underwent a repair procedure under cardiopulmonary bypass.

Results: All patients survived. Group A had lower values of operation time, mechanical ventilation time, cardiac intensive care unit duration and amount of blood transfusion. Nevertheless, postoperative hospitalization time between two groups showed no statistical difference. In group A, 109 (85.83%) patients were successfully occluded, whereas 18 (14.17%) patients were converted to open-heart surgery. No severe complications occurred in the follow-up period.

Conclusion: Intraoperative device closure is safe, effective procedure for selected cases with secundum ASDs which were not referred to percutaneous closure because of more suitable occluder selection, no "unbutton effect" and stitching enhancement.

KEYWORDS

children, intraoperative device closure, percutaneous closure, secundum ASD

1 | INTRODUCTION

Atrial septal defect (ASD) is the third most common type of congenital heart disease, with an estimated incidence of 1.64 per 1000 live births worldwide.¹ Secundum ASD is a defect within the fossa ovalis usually due to one or several defects within septum primum.² Percutaneous closure for secundum ASD is widely accepted as an alternative to surgical repair because of its high successful rate, low incidence of complications, and short hospitalizations.³⁻⁵ With

newer device and development of technology, the boundary of contraindication has been being constantly broken. However, some unsuitable children still are recommended to surgical closure based on transthoracic echocardiographic (TTE) diagnosis or cardiac catheterization. With appearance of intraoperative device closure, some secundum ASD recommended to surgical repair could be deferred to device closure.^{6,7} The aim of this study was to review our single center experience of strategy selection of treating secundum ASD not referred to percutaneous closure.

TABLE 1 Patient profiles of two groups

	Group A	Group B	P value
Total number	127	104	
Male/female	65/62	59/45	.400
Mean age (months)	37.5 ± 16.7	39.2 ± 15.8	.216
Mean weight (kg)	15.2 ± 8.3	16.7 ± 9.4	.100
ASD			
Large defect, diameter >25 mm	2	15	<.001
Weight <15 kg	88	76	.528
Age <3 years	91	85	.074
Deficient rim	67	72	.011
IVC rim	21	19	.729
Posterior rim	13	7	.346
IVC and posterior rim	8	16	.024
Aortic and superior rim	25	9	.019
>3 rims	0	21	<.001
Multiple defects	14	32	<.001
Associated with other malformation			
with VSD	38	29	.734
with PDA	4	8	.122
with PS	17	21	.165
with >2 other malformations	2	8	.023
Associated with valve regurgitation (≤mild)			
Mitral valve	4	7	.204
Aortic valve	6	10	.145
Tricuspid valve	9	8	.861
Associated with arrhythmia			
IRBBB	16	15	.686

Abbreviations: ASD, atrial septal defect; IVC, inferior vena cava; VSD, ventricular septal defect; PDA, patent ductus arteriosus; PS, pulmonary stenosis; IRBBB, incomplete right bundle brunch block. P value, between group A and group B.

2 | MATERIAL AND METHODS

2.1 | Clinic materials

From April 2010 to December 2018, 231 secundum ASD children (≤14 years) directly recommended to surgical repair were enrolled in this study. The following selection criteria were applied: (1) percutaneous closure was rejected by cardiologist; (2) no other malformations required surgical repair under cardiopulmonary bypass (CPB); (3) more than mild atrioventricular valve regurgitation was excluded; (4) the existence of aortic valve prolapse with regurgitation was excluded; (5) secundum ASD deficient rim (<5 mm) was included; (6) posterior-inferior circumferentia of defect was

detected as deficient rim >1/4 (0°-90°view under transesophageal echocardiography [TEE]) was excluded; (7) diameter of ASD >30 mm was excluded.

These patients were divided into 2 groups according to the parents' choice based on surgeons' recommendation. In Group A, 127 patients underwent an initial attempt at device closure. In Group B, 104 patients underwent a repair procedure under CPB. There were some statistically significant differences in the clinical data between the two groups ($P > .05$). Detailed patient profiles are given in Table 1. All risks of two procedures were informed to the parents and informed consents were obtained. The study was approved by the Committee on Clinical Trials at the Second Xiangya Hospital.

2.2 | Procedure

2.2.1 | Group A

All patients underwent general anesthesia. Transoesophageal echocardiographic (TEE) (Vivid 7 Dimension; GE, Waukesha, Wisconsin) was performed before and through the operation. The device and the delivery systems (Shanghai Shape Memory Alloy Co., Ltd, Shanghai, China) used in this cohort were specially designed for this procedure and approved by the Food and Drug Administration of China. The device is fixed onto a 0.035 in. delivery cable made of stainless steel by a microscrew system and attached by a 3-0 Prolene suture (Ethicon, Inc, Somerville, New Jersey), called a safe wire in the case of detachment of the occluder from the delivery leader, that is sewn onto the right side of the disc for retrieval should occluder dislocation occur and is cut and removed after the procedure. The free wall of the right atrial (RA) was exposed via a 2-cm incision in the inferior sternum. Patients were systemically heparinized by intravenous heparin sodium (1 mg/kg). A purse-string suture by 4-0 Prolene (Ethicon, Inc) was placed around the chosen puncture site. Thereafter, we cut a 2 mm incision on puncture site of RA by scalpel. The loading sheath attached to the delivery sheath and the device was pushed forward through the incision to LA. The left side of the disc was deployed and the occluder was retracted against the septum. The delivery sheath was pulled back again, and the waist and right side of the disc were subsequently released. TEE was performed to ensure that there were no residual shunts or valve regurgitation. A prophylactic antibiotic was given during the procedure and the day after. Aspirin (3 mg/kg/day) was routinely given for 6 months.

2.2.2 | Size selection of occlude

We adopt area rule instead of diameter rule which was employed in most center.

Area rule: for oval ASD: $d_o = \frac{2\sqrt{1.2(\pi \times a \times b)}}{\pi}$ (d_o : diameter of occluder; a : semimajor axis; b : semiminor axis); for circular ASD: $d_o = \frac{2\sqrt{1.2\pi r^2}}{\pi}$ (d_o : diameter of occluder; r : radius of circle).

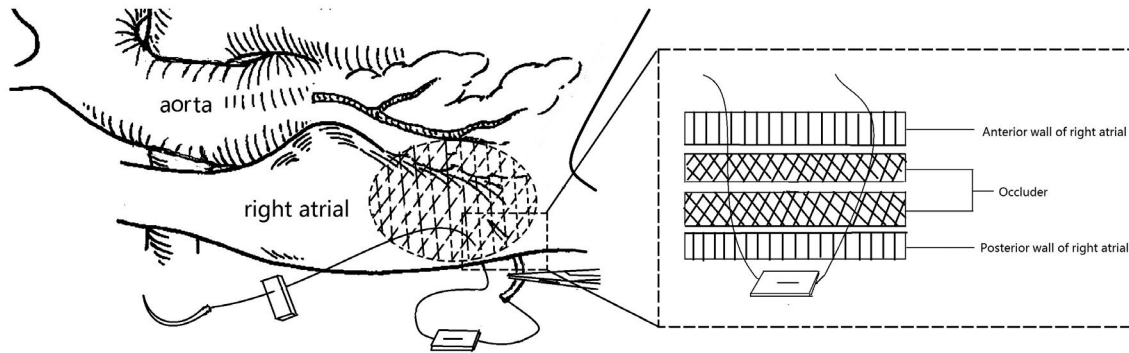


FIGURE 1 Stitching enhancement for cases with deficient posterior or inferior rim. 1-2 stitches through the RA free wall and posterior rim of occluder with 2/0 (>10 kg) or 3/0 prolene (\leq 10 kg)

2.2.3 | Large ASD

Because of the age limitation, we defined >25 mm as large ASD. Smaller occluder (based on area rule) was employed for larger ASD for avoiding atrioventricular block.

2.2.4 | Deficient rim

When the aortic or superior rim was deficient, the small-edge occluder was employed and area rule was adopted.

However, when the posterior-inferior was deficient, the normal occluder was implanted. Then once occluder was implanted, the stability and safety were evaluated by TEE. Unstable occlusion was defined as posterior-inferior circumference of defect was detected as deficient rim $\geq 1/8$ (0° - 90° view under TEE). More than 2-mm residual shunt was defined as unacceptable residual shunt. Then we sewed 1-2 stitches through the RA free wall and posterior rim of occluder with 2/0 (>10 kg) or 3/0 prolene (\leq 10 kg) (Ethicon, Inc) (Figure 1).

2.2.5 | Multiple ASDs

Bigger occluder (usually larger than diameter of ASD 4-6 mm) was employed in the biggest defect or small-waist-big-edge occluder was employed for covering smaller defect.

2.2.6 | Associated with other closable cardiac malformation

The technical details regarding closure of the multiple congenital heart defects have been described in the previous reports.⁷

Upon occlusion failure, the patients' incision in the inferior sternum was lengthened and a median sternotomy was made. The patients then underwent the same surgical procedure as in Group B.

2.2.7 | Group B

All patients underwent open-heart surgery with partial sternotomy. The ASDs were closed using continuous suture with pericardial patch.

2.2.8 | Follow-up

Follow-up evaluations were adopted at 2 weeks, 3 months, 6 months, and 12 months after the procedure and yearly thereafter. Follow-up visits included electrocardiograms and TTE.

2.3 | Statistical analysis

SPSS 22.0 (IBM, Armonk, New York) was used for the data analyses. Continuous variables are expressed as mean \pm standard deviation. Differences between the 2 groups were analyzed using independent-samples *t* test for continuous variables and chi-square test for categorical variables. Paired-samples *t* test was used to compare differences of variables pre- and postprocedurally. A *P* value <0.05 was statistically significant.

3 | RESULTS

All patients survived no acute procedural complications or severe adverse events (death, valve injury, complete atrioventricular block, or embolism) occurred.

Group A had lower values of operation time, mechanical ventilation time, cardiac intensive care unit duration and amount of blood transfusion. Nevertheless, postoperative hospitalization time between two groups showed no statistical difference (Table 2).

3.1 | Occlusion

One hundred nine (85.83%) patients were successful occluded, whereas 18 (14.17%) patients were converted to open-heart surgery after occlusion attempt failure. The average occluded ASD diameter was 17.19 ± 4.98 mm (8-30 mm) and the average occluder diameter was 19.06 ± 5.77 mm (12-32 mm). About 103 patients were completely closed and 6 (5.50%) were detected as trivial residual shunt (width ≤ 2 mm) at the moment of closure. Four cases with residual shunt of them disappeared when discharging from hospital.

TABLE 2 Comparison of occlusion (Group A) and open-heart surgery (Group B)

	Time of operation (min)	Time of mechanical ventilation (min)	Time in ICU (min)	Length of stay after surgery (day)	Amount of blood transfusion	RBC plasma
Group A	48.21 ± 6.72	112.37 ± 7.30	321.24 ± 36.21	4.59 ± 1.31	0.13 ± 0.23u	0 ml
Group B	98.22 ± 29.13	159.68 ± 12.96	352.56 ± 54.15	4.77 ± 1.56	0.72 ± 0.18u	23.57 ± 12.25 ml
P value	<.01	<.01	<.01	.36	<.01	<.01

Values are mean ± standard deviation.

Abbreviations: ICU, intensive care unit; RBC, red blood cell; Group A, patients underwent device closure; Group B, patients underwent repair procedure. P value, between group A and group B.

Binary logistic regression showed that none of the indices (gender, age, weight, distance to every rim, multiple ASD, with VSD, and diameter of ASD/atrial septum) showed significant differences in the closure failure rates. Distance to posterior–inferior rim ≤2 mm was a predictor for residual shunt (odds ratio, 1.9; 95% confidence interval, 1.41–2.69; $P = .029$) and other indices was not related with complications.

3.2 | Surgical repair

The average diameter of ASD in surgery repair was 18.06 ± 5.33 mm ($P = .202$). Trivial residual shunt was detected in two patients (1.92%) upon discharge ($P = .362$). Binary logistic regression showed that none of the indices (gender, age, weight, distance to posterior–inferior rim, multiple ASD, with VSD, and diameter of ASD/atrial septum) showed significant differences in complication rates.

3.3 | Converting to surgery

Eighteen patients in group A underwent converting to surgery were closed successfully and had no severe adverse events. The reasons of 13 converting were unacceptable residual shunt (width ≥2 mm, velocity ≥2 m/s) and 5 were atrioventricular block. No complication occurred after surgery and 5 atrioventricular blocks recovered after operation. No severe complications occurred in these 18 patients in the follow-up period.

3.4 | Follow-up results

The patients were followed by clinical examination, echocardiography and TTE at the 2nd week, 1st month, 3rd month, 6th month, 1st year, 2nd year, 3rd year, and 4th year. The follow-up rates at the 2nd week, 1st month, 3rd month, 6th month, 1st year, 2nd year, 3rd year, and 4th year were 100%, 100%, 100%, 100%, 100%, 100%, 95.12%, and 91.42%, respectively. No severe adverse events (embolism, complete atrioventricular block, valve injury, or death) were noted during the period of 3–96 months (median, 40.54 months). All trivial residual shunts disappeared in the follow-up period.

3.5 | Complications

No severe complications occurred in the follow-up period. However, some complications needed expectant treatment occurred after

operation and in the follow-up period. The most frequent complications were hydropericardium and incomplete right bundle (IRBBB). All complications occurred in first month after operation and were cured by conservative treatment (such as hydropericardium by diuretics and poor wound healing by wound dressing) or remain harmless (such as IRBBB). Detailed complications are given in Table 3.

4 | DISCUSSION

Closure for ASD, especially in childhood may improve survival in ASD patients.⁸ Evidence clearly suggested that untreated large secundum defects are associated with a reduced lifespan. Campbell reported a low annualized mortality rate in the first two decades of life (0.6% and 0.7% per year, respectively), increasing to 4.5% per year in the fourth decade and 7.5% per year in the sixth decade.⁹

Percutaneous closure guided by digital subtraction angiography (DSA) was the first choice for secundum ASD.¹⁰ We also reported that using a modified delivery system and a reestablished procedure, the percutaneous closure of ASD without fluoroscopy is a possible alternative treatment.¹¹ Our center had established a whole strategy for treating ASD and the flow chart is showed in Figure 2.

Too large defect is the first major reason for no percutaneous closure. Especially large defect often accompanied with soft rim.

TABLE 3 Complications of 2 groups

	Group A	Group B	P value
Total number	127	104	
Discharge			
Hydropericardium	3	4	.512
New IRBBB	13	18	.116
Poor wound healing	1	1	.698
2nd week			
Hydropericardium	1	2	.690
New IRBBB	3	2	.735
Poor wound healing	0	1	.880
1st month			
Hydropericardium	0	1	.880
Poor wound healing	1	0	.881

Abbreviation: IRBBB, incomplete right bundle branch block. P value, between group A and group B.

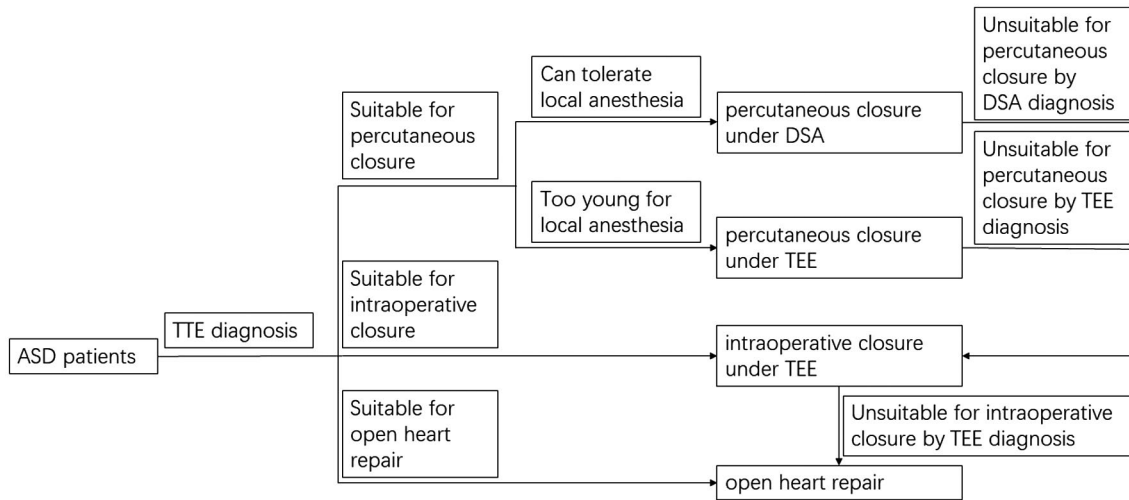


FIGURE 2 The flowchart of treating ASD

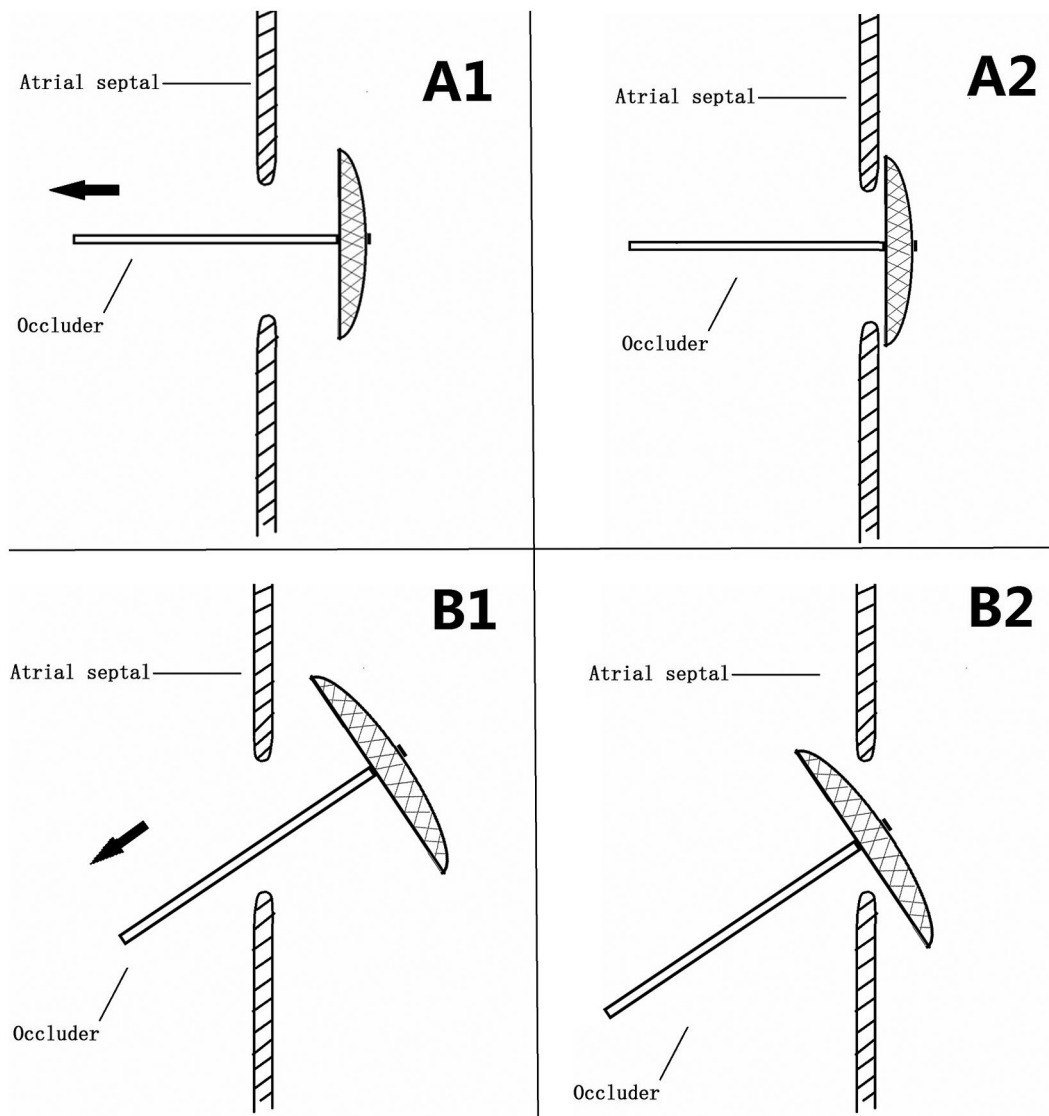


FIGURE 3 Unbutton effect. A, When loading sheath is vertical to defect in intraoperative device closure, left disc was evenly pulled and held. B, when loading sheath is angulate to defect in percutaneous closure, left disc was easy to be pulled out like unbutton

The loading sheath was vertical to defect in intraoperative device closure but angulate in percutaneous closure. "Unbutton effect" may occur in percutaneous closure with the same size of occluder (Figure 3). So oversize occluders were more often selected in percutaneous closure. Oversize occluders were associated with embolization and erosion which are the most feared consequences in percutaneous closure.^{12,13} Moreover, balloon sizing for defect is golden standard in traditional percutaneous closure¹⁴ which results in increased risk of tearing of septum, and excess irradiation.^{15,16} TEE sizing had been proved same accuracy with almost noninvasive.¹⁷ In this study, we adopted area rule instead of diameter rule which was employed in most center. The average occluded ASD diameter was 17.19 ± 4.98 mm (8-30 mm) and the average occluder diameter was 19.06 ± 5.77 mm (12-32 mm). Smaller but suitable occluder can avoid embolization and erosion to the full extent. Smaller occluder means more rapid endothelialization and this could avoid complication from incomplete endothelialization like occluder displacement and so on. In the 8 years follow up, no embolization, erosion or occluder displacement occurred.

Deficient rim, especially deficient posterior-inferior rim is the another major reason for suggesting to surgery. Only a few previous reports validated percutaneous closure in cases with deficient rims.¹⁸⁻²¹ Deficient aortic or superior rim may cause erosion of aortic valve and deficient posterior or inferior rim may cause displacement of occluder. However, using more accurate assessment tools is the only way to improve the success rate in percutaneous closure procedure.²¹ In this study, small-edge occluder (right disc > waist 3 mm different from normal occluder right disc > waist 5 mm) was employed and area rule was adopted for cases with deficient aortic or superior rim because of no "unbutton effect" in intraoperative device closure. Stitching enhancement for cases with deficient posterior or inferior rim strengthens the stability of occluder to avoid from displacement.

Multiple ASDs remains a challenge for percutaneous closure because of residual shunt.²² Zhu et al²³ had introduced a new atrial septum remodeling technique by breaking the rim between multiple ASDs for intraoperative device closure. In this study, bigger occluder (usually larger than diameter of ASD 4-6 mm) was employed in the biggest defect or small-waist-big-edge occluder (right disc-waist 7 mm different from normal occluder right disc > waist 5 mm) was employed for covering smaller defect.

For some cases with other cardiac malformation, sometimes the ASD can be closed by percutaneous closure but other cardiac malformation cannot be closed. Nonetheless, intraoperative device closure also expanded indications for other cardiac malformation, especially for some ventricular septal defects.^{7,24-27}

In this study, all patients underwent intraoperative device closure got satisfactory results and avoided cardiopulmonary bypass. For secundum ASD, our center had established whole closure strategy including percutaneous closure,¹¹ intraoperative device closure and surgical repair by TEE guiding merely. TEE guiding platform may become the supplement of DSA guiding for treating structural heart disease.

All patients got appropriate therapy in this study. Even though device closure group had lower values of operation time, mechanical ventilation time, cardiac intensive care unit duration, and amount of blood transfusion, the postoperative hospitalization times were similar between two groups. In conclusion, the curative effects between two methods were the same but patients of group A had avoided CPB.

The feasibility of device closure for secundum ASDs which were not referred to percutaneous closure had been proven in this study. However, longer term follow-up and larger samples in multicenter are needed.

5 | CONCLUSION

For secundum ASDs which were not referred to percutaneous closure, surgical repair is not the only way to close the defect. Intraoperative device closure is safe, effective procedure for selected cases because of more suitable occluder selection, no "unbutton effect" and stitching enhancement.

CONFLICT OF INTEREST

On behalf of all authors, the corresponding author states that there is no conflict of interest.

AUTHOR CONTRIBUTIONS

Fei Zhang contributed in drafting article.
Yifeng Yang approved the article.
Qin Wu collected the data.
Wancun Jin collected the data.
Haisong Bu analyzed the data.
Sijie Wu involved in statistics.
Tianli Zhao devised the concept.
Shijun Hu designed and critically revised the article.

REFERENCES

- van der Linde D, Konings EE, Slager MA, et al. Birth prevalence of congenital heart disease worldwide: a systematic review and meta-analysis. *J Am Coll Cardiol*. 2011;58(21):2241-2247.
- Geva T, Martins JD, Wald RM. Atrial septal defects. *Lancet*. 2014;383(9932):1921-1932.
- Du ZD, Hijazi ZM, Kleinman CS, Silverman NH, Larntz K. Comparison between transcatheter and surgical closure of secundum atrial septal defect in children and adults: results of a multicenter nonrandomized trial. *J Am Coll Cardiol*. 2002;39(11):1836-1844.
- Butera G, Biondi-Zoccai G, Sangiorgi G, et al. Percutaneous versus surgical closure of secundum atrial septal defects: a systematic review and meta-analysis of currently available clinical evidence. *EuroIntervention*. 2011;7(3):377-385.
- Kutty S, Hazeem AA, Brown K, et al. Long-term (5- to 20-year) outcomes after transcatheter or surgical treatment of hemodynamically significant isolated secundum atrial septal defect. *Am J Cardiol*. 2012;109(9):1348-1352.

6. Zhao T, Yang Y, Xu X, et al. Transesophageal echocardiographic guidance of percardiac device closure of intracardiac defects in patients weighing less than 10 kg. *J Card Surg*. 2012;27(6):740-744.
7. Hu S, Yang Y, Zhu Y, et al. Experience with percardiac interventions for multiple congenital heart diseases in children. *Interact Cardiovasc Thorac Surg*. 2014;19(5):812-815.
8. Nyboe C, Karunanithi Z, Nielsen-Kudsk JE, Hjortdal VE. Long-term mortality in patients with atrial septal defect: a nationwide cohort study. *Eur Heart J*. 2018;21;39(12):993-998.
9. Campbell M. Natural history of atrial septal defect. *Br Heart J*. 1970;32(6):820-826.
10. Turner DR, Owada CY, Sang CJ, Khan M, Lim DS. Closure of secundum atrial septal defects with the AMPLATZER septal occluder. A prospective, multicenter, post-approval study. *Circ Cardiovasc Interv*. 2017;10(8): pii:e004212.
11. Yang Y, Zhang W, Wu Q, Gao L, Jin W, Zhao T. Transcatheter closure of atrial septal defects without fluoroscopy: a well-established procedure for alternative use in children. *EuroIntervention*. 2016;12(5):e652-e657.
12. Ostermayer SH, Srivastava S, Doucette JT, et al. Malattached septum primum and deficient septal rim predict unsuccessful transcatheter closure of atrial communications. *Catheter Cardiovasc Interv*. 2015;86(7):1195-1203.
13. McElhinney DB, Quartermain MD, Kenny D, Alboliras E, Amin Z. Relative risk factors for cardiac erosion following transcatheter closure of atrial septal defects: a case-control study. *Circulation*. 2016;133(18):1738-1746.
14. King TD, Thompson SL, Mills NL. Measurement of atrial septal defect during cardiac catheterization. Experimental and clinical results. *Am J Cardiol*. 1978;41(3):537-542.
15. Harikrishnan S, Narayanan NK, Sivasubramonian S. Sizing balloon-induced tear of the atrial septum. *J Invasive Cardiol*. 2005;17(10):546-547.
16. Vijarnsorn C, Durongpisitkul K, Chanthong P, et al. Transcatheter closure of atrial septal defects in children, middle-aged adults, and older adults: failure rates, early complications; and balloon sizing effects. *Cardiol Res Pract*. 2012;2012:584236.
17. McGhie JS, van den Bosch AE, Haarman MG, et al. Characterization of atrial septal defect by simultaneous multiplane two-dimensional echocardiography. *Eur Heart J Cardiovasc Imaging*. 2014;15(10):1145-1151.
18. Du ZD, Koenig P, Cao QL, Waight D, Heitschmidt M, Hijazi ZM. Comparison of transcatheter closure of secundum atrial septal defect using the Amplatzer septal occluder associated with deficient versus sufficient rims. *Am J Cardiol*. 2002;90(8):865-869.
19. Papa M, Gaspardone A, Fragasso G, et al. Feasibility and safety of transcatheter closure of atrial septal defects with deficient posterior rim. *Catheter Cardiovasc Interv*. 2013;81(7):1180-1187.
20. Thanopoulos BD, Dardas P, Ninios V, Eleftherakis N, Karanasios E. Transcatheter closure of large atrial septal defects with deficient aortic or posterior rims using the "Greek maneuver". A multicenter study. *Int J Cardiol*. 2013;168(4):3643-3646.
21. Assaidi A, Sumian M, Mauri L, et al. Transcatheter closure of complex atrial septal defects is efficient under intracardiac echocardiographic guidance. *Arch Cardiovasc Dis*. 2014;107(12):646-653.
22. Kijima Y, Akagi T, Nakagawa K, Takaya Y, Oe H, Ito H. Three-dimensional echocardiography guided closure of complex multiple atrial septal defects. *Echocardiography*. 2014;31(10):E304-E306.
23. Zhu D, Meng W, Liang M, et al. Intra-operative device closure of multiple atrial septal defects facilitated by a unique atrial septum remodeling technique: initial results and experience in 11 patients. *Eur J Cardiothorac Surg*. 2012;41(2):266-271.
24. Liu L, Zhao TL, Yang YF, et al. Intraoperative device closure of subaortic ventricular septal defects. *J Card Surg*. 2013;28(4):456-460.
25. Gao Z, Wu Q, Zhao T, et al. A minimally invasive technique for occluding large muscular ventricular septal defects in infants. *Cardiology*. 2014;127(3):196-202.
26. Hu S, Yang Y, Wu Q, et al. Results of two different approaches to closure of subaortic ventricular septal defects in children. *Eur J Cardiothorac Surg*. 2014;46(4):648-653.
27. Yang Y, Gao L, Xu X, et al. Echocardiographic assessment and guidance in minimally invasive surgical device closure of perimembranous ventricular septal defects. *Heart Surg Forum*. 2014;17(4):E206-E211.

How to cite this article: Zhang F, Yang Y, Wu Q, et al. Strategy of treating secundum atrial septal defect not referred to percutaneous closure. *Congenital Heart Disease*. 2019;14:324-330. <https://doi.org/10.1111/chd.12753>