

# Anticipatory perioperative management for patent ductus arteriosus surgery: Understanding postligation cardiac syndrome

Regan E. Giesinger MD, FRCPC<sup>1</sup>  | Adrienne R. Bischoff MD<sup>3</sup> |  
Patrick J. McNamara MB, MRCPH, MSC<sup>1,2</sup>

<sup>1</sup>Department of Pediatrics, University of Iowa, Iowa City, Iowa

<sup>2</sup>Department of Internal Medicine, University of Iowa, Iowa City, Iowa

<sup>3</sup>Department of Pediatrics, University of Toronto, Toronto, Canada

## Correspondence

Patrick J. McNamara, MB, MRCPH, MSC, Pediatrics and Internal Medicine, Neonatology, University of Iowa, 200 Hawkins Dr, Iowa City, IA 52242.  
Email: Patrick-mcnamara@uiowa.edu

## Abstract

Ligation of a hemodynamically significant ductus arteriosus results in significant changes in loading conditions which have predictable consequences. Postligation cardiac syndrome, defined as hypotension requiring inotropic support and failure of oxygenation and ventilation, may occur 6-12 hours following ligation due to left ventricular systolic and diastolic failure, respectively. Afterload is the primary driver of this decompensation. In this review, we describe the pathophysiological changes in loading conditions associated with postligation cardiac syndrome and other contributors to cardiovascular dysfunction following ductal ligation. We present strategies for perioperative optimization and a physiology-based algorithm for postoperative management guided by targeted neonatal echocardiography. The use of these strategies to reduce the frequency of postligation deterioration may be an avenue to improve outcomes for neonates in this vulnerable patient population.

## KEYWORDS

patent ductus arteriosus ligation, postligation cardiac syndrome, targeted neonatal echocardiography

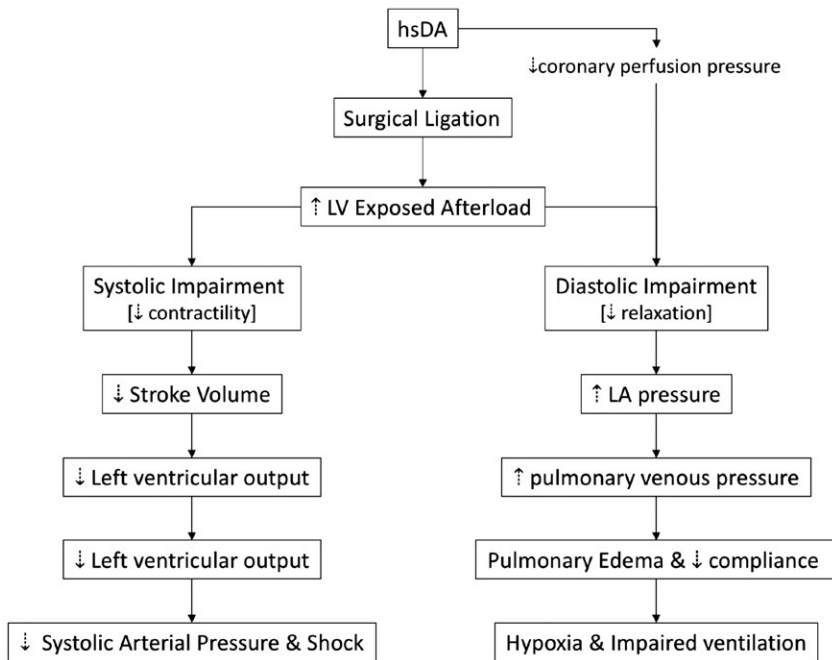
## 1 | INTRODUCTION

The role of surgical ligation for infants with systemic circulatory and/or respiratory compromise in the presence of a high-volume ductal shunt remains controversial. A secular trend away from ductal closure and toward a more permissive, conservative approach<sup>1</sup> may, in part, be related to fears about the impact of ligation on neurosensory outcome.<sup>2,3</sup> Although confounding by indication makes observational studies of ductal ligation challenging to interpret,<sup>4</sup> postoperative physiological instability may play a role in outcome. Postligation cardiac syndrome (PLCS), defined as systolic arterial pressure less than the third percentile requiring vasopressors with associated ventilation and oxygenation failure, has been reported in 28%-45% of overall cases.<sup>5-7</sup> Recent literature suggests that neonates who

experience PLCS have higher mortality<sup>6</sup> and may be at particular risk of severe bronchopulmonary dysplasia, thereby raising a question as to the role of perioperative cardiovascular status on other neonatal outcomes.<sup>8</sup> Anticipatory management and targeted therapy, therefore, may at minimum mitigate short-term hypoxia and hypoperfusion, and perhaps present an avenue to improve outcomes.

## 2 | MALADAPTATION FOLLOWING HSDA LIGATION

The primary determinants of transductal flow are the intraluminal diameter and the relative pressure gradient, with other factors such as blood viscosity, playing a role as governed by Poiseuille's Law. It is, therefore, common for infants with high-volume left-to-right shunt to have relatively low pulmonary artery pressure (PAP) in comparison



**FIGURE 1** Physiological changes following ligation of a hemodynamically significant ductus arteriosus. Surgical ligation is associated with an increase in left ventricular afterload which has implications for left ventricular systolic and diastolic function. Abbreviations: hsDA, hemodynamically significant ductus arteriosus; LA, left atrium; LV, left ventricle

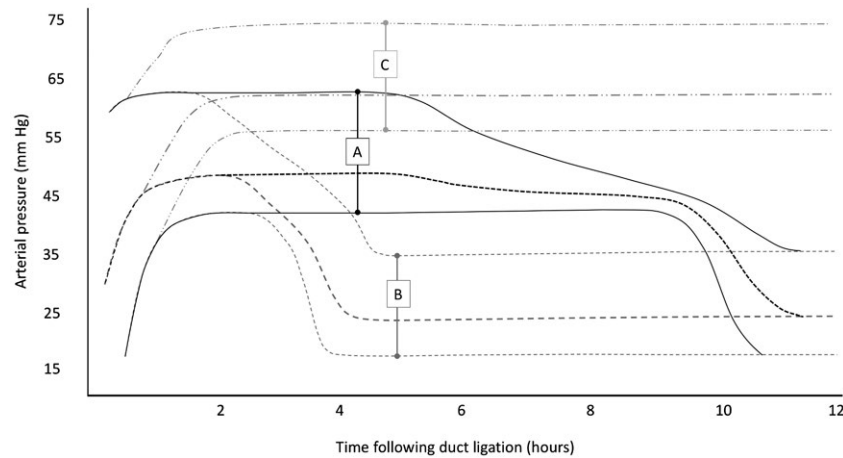
to systemic arterial pressure (SAP). Surplus pulmonary blood flow contributes to impaired lung compliance<sup>9</sup> and high left atrial preload which produces dilation of left heart structures. A reduction in postductal systemic blood flow may occur<sup>10</sup> and may be associated with impaired organ performance. Some neonates manifest low systemic arterial pressure, particularly in the first postnatal week<sup>11</sup> which may not be seen in the established shunt. In animal models of chronic shunt, compensatory mechanisms by the circulatory system occur to increase systemic vascular tone in an effort to maintain organ perfusion pressure.<sup>12</sup> Although human neonatal literature is not available, similar biological mechanisms may occur. Following surgical ligation of those ducts with low PAP, high SAP, and high-volume shunt, sequential changes in loading conditions result in predictable consequences (Figure 1).

Immediate cessation of left-to-right shunt reduces pulmonary blood flow and thereby left atrial preload resulting in a proportional reduction in cardiac output. It is important to note, that unless the patient is volume depleted, the reduction in preload represents a return to “normal” loading conditions from “high” and typically does not constitute true left heart hypovolemia. Because the neonatal Frank-Starling curve is relatively flat above a critical filling volume, there is typically limited impact of this change on contractility and the timing of the reduced preload does not coincide with the timing of clinical decompensation. Exceptions may occur, for example, the situation where left-to-right shunt was supporting normal cardiac output, for example, following aggressive fluid restriction or diuresis prior to surgery, acute illness complicated with third space losses, or in the setting of acute surgical blood loss.<sup>13</sup> Normalization of pulmonary blood flow results in improved compliance<sup>9</sup> and excessive mean airway pressure may also contribute to impaired pulmonary venous return in the immediate period following closure. Simultaneously, removal of the lower pressure pulmonary circuit results in an increase

in left ventricular exposed afterload, to which the immature myocardium may be poorly able to adapt.<sup>13</sup> This may be related to, among other things, a paucity of contractile tissue,<sup>14</sup> disorganized myofibrillar arrangement,<sup>15,16</sup> and immature calcium handling<sup>15</sup> as compared to the mature heart. Human and animal studies have demonstrated a temporal correlation between peak exposure to afterload, left heart dysfunction, and clinical instability at 6-12 hours postligation<sup>17,18</sup> suggesting that afterload is an important contributor to left heart systolic and diastolic dysfunction.

### 3 | POSTOPERATIVE CLINICAL PHENOTYPIC CONTINUUM

Following ligation, diastolic arterial pressure immediately increases due to loss of the pulmonary vascular bed and resultant increase in resting pressure against the systemic vessel walls, while systolic arterial pressure remains relatively unchanged. PLCS is a phenotype which presents between 6 and 12 hours postoperatively with hypotension and poor perfusion requiring inotrope therapy and progressively impaired ventilation and oxygenation due to LV failure. Typically, patients who go on to develop PLCS have a period of stable oxygenation and perfusion for 6-12 h during which the myocardium is compensating for changes in loading conditions and signs of impaired circulation have not yet manifested (Figure 2). Early findings of postligation may include decline in systolic arterial pressure with preserved mean as cardiac output declines due to LV systolic dysfunction but systemic vascular resistance remains high.<sup>19</sup> Over a similar time course, LV diastolic dysfunction contributes to pulmonary edema, declining lung compliance and deteriorating ventilation and oxygenation.<sup>19</sup> If circulatory support is not provided, systolic hypotension may progress to poor perfusion, acidosis, and combined



**FIGURE 2** Possible blood pressure trajectories following surgical ligation. A, Progressive decline in systolic arterial pressure followed by rapid decompensation in both mean and diastolic arterial pressure due to left ventricular failure. This pattern is associated with the clinical entity of postligation cardiac syndrome. B, Early severe drop in both systolic and diastolic arterial pressure which may be due to the impaired left ventricular preload (eg, hemorrhage, pneumothorax) or adrenal insufficiency. C, Sustained high mean and diastolic arterial pressure with normal pulse pressure which may result in pulmonary edema and hypoxia

reduction in systolic and diastolic (and therefore mean) arterial pressure. PLCS is not the only cause of postoperative cardiorespiratory instability; other causes include surgical complications (eg, pneumothorax, chylothorax, and hemorrhage) and adrenal dysfunction. Both surgical complications and adrenal impairment may present early (0–4 h). Immediate respiratory compromise with the later development of hypotension should prompt investigation for the former and routine postoperative chest radiography is recommended in all patients. Progressive systolic and diastolic hypotension is the most prominent feature of adrenal insufficiency and should prompt early initiation of hydrocortisone. It is important to identify the physiologic nature of postoperative decompensation in order to ensure precision of management. The time line and changes in blood pressure may aid in identifying each phenotype.

Some neonates, either due to the intrinsic resilience of LV systolic performance or due to early initiation of inotrope or afterload reducing therapy, may exhibit signs of isolated LV diastolic impairment without features of a low cardiac output state. Hallmark findings include systemic hypertension and evolution of impaired oxygenation and ventilation, which is associated with pulmonary edema on chest radiography.<sup>20</sup> Though not classic PLCS, this phenomenon may contribute to postoperative escalation of ventilator support and may last for several days. The pathophysiologic contributors to this phenotype remain unclear and further study of risk factors and natural history is warranted.

#### 4 | RISK FACTORS FOR PLCS

The vulnerability of the myocardium to changes in afterload is likely developmentally regulated. Younger neonates (fewer than 28 days postnatal age) and those with lower body weight (less than 1 kg) are at an increased risk of PLCS.<sup>19</sup> Though the magnitude of shunt volume has not, thus far, been associated with PLCS risk it is probable

that the relative change in exposed vascular resistance faced by the LV plays a role. Neonates with high pulmonary pressure, either due to intrinsic pulmonary arterial hypertension or due to chronic exposure to high-volume shunt, theoretically may have a lower likelihood of developing PLCS as the lesser change in afterload may protect the LV from failure. The optimum timing of surgical ligation to balance the risks of PLCS with the benefits, which may include reduced respiratory and nutritional morbidity,<sup>21</sup> remains unclear. An approach which minimizes exposure to high-volume shunt and employs strategies to reduce PLCS risk as described below is recommended.

#### 5 | PERIOPERATIVE OPTIMIZATION

To mitigate the risks due to the changes in loading conditions, physiological stress, and complications associated with thoracotomy and lung retraction, preoperative optimization of several factors is recommended.<sup>22</sup> First, optimization of volume status is prudent. Aggressive fluid restriction and diuretic therapy may further deplete the systemic blood flow to already compromised postductal organs and has been shown to have little impact on shunt volume.<sup>23</sup> Because volume loading in the perioperative period has not been shown to prevent postoperative hypotension,<sup>24</sup> and to prevent preload related intraoperative decompensation, euvolemia is recommended. Second, respiratory stability is an important consideration during and after thoracotomy. No specific respiratory strategy has been associated with improved outcomes surround PDA ligation and ventilation using high-frequency modes has been suggested as equivalent to conventional ventilation in centers where the surgical, anesthetic and neonatal intensive care teams are experienced with this approach.<sup>25</sup> Surgical exposure of the PDA, however, requires lateral positioning and lung retraction which may significantly alter pulmonary mechanics intraoperatively. It is important that adequate distending pressure to prevent atelectasis is maintained throughout

the case and that an appropriate sized endotracheal tube without excessive leak is well secured, particularly if using conventional ventilatory modes. It is prudent to ensure that the neonate is stable on similar settings as will be used intraoperatively for 6-8 h prior to surgery. Finally, preoperative assessment of adrenal performance may have several benefits. Developmental immaturity of the hypothalamic-pituitary-adrenal axis and adrenal hypoperfusion due to chronic ductal steal are potential contributors to early postoperative hypotension (0-4 h)<sup>7,26,27</sup> and poor response to catecholamine therapy is associated with low postoperative serum cortisol.<sup>7</sup> The use of postoperative cortisol, however, may lead to delay in treatment, random serum cortisol levels do not predict PLCS<sup>28</sup> and prophylactic stress dose hydrocortisone for all infants is not associated with improved outcomes.<sup>29</sup> Preoperative serum cortisol following adrenocorticotropic hormone (ACTH) stimulation of less than 750 nmol/L, however, has been associated with PLCS<sup>26</sup> and preoperative assessment of adrenal performance may facilitate early administration to appropriately selected patients. Stress dose hydrocortisone should be considered for infants already receiving preoperative steroids for lung disease or hypotension<sup>29</sup> as well as for symptomatic patients particularly in the setting of a failed ACTH stimulation test.<sup>22</sup>

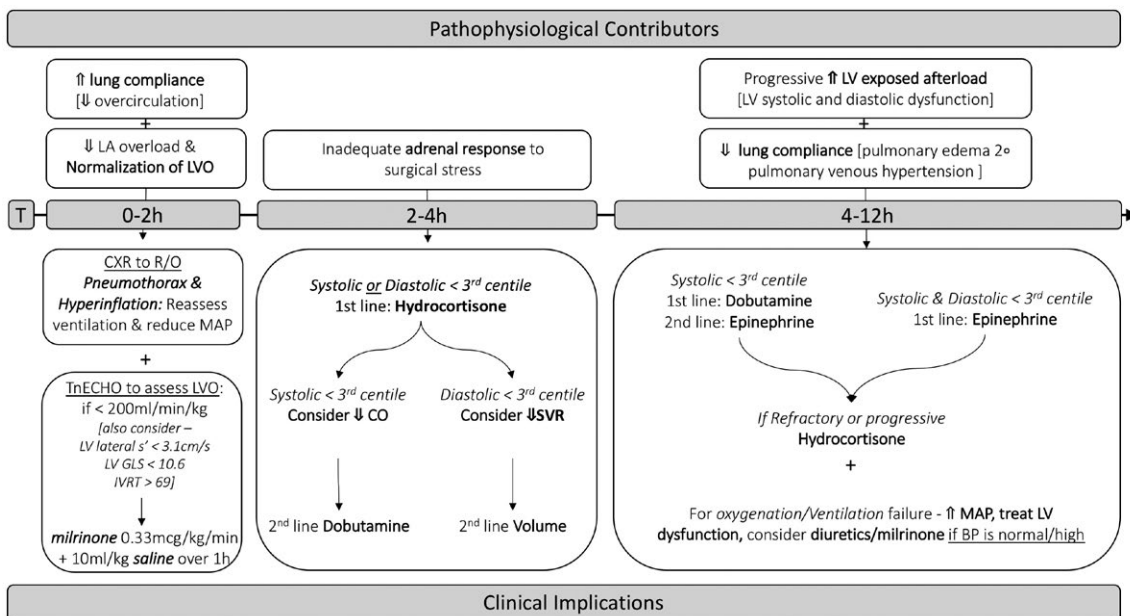
## 6 | TARGETED NEONATAL ECHOCARDIOGRAPHY GUIDED POSTOPERATIVE MANAGEMENT

Early targeted neonatal echocardiography (TnECHO) is a useful tool to predict neonates at risk of PLCS. While conventional indices of left ventricular (LV) systolic performance (eg, fractional shortening,

ejection fraction) are not predictive of PLCS,<sup>30,31</sup> LV output less than 200 mL/kg/min 1 hour postligation is a sensitive predictor of cardiorespiratory instability and need for inotropic support.<sup>32</sup> Other novel measures of LV performance including global longitudinal strain and myocardial velocity as measured at the mitral valve annulus by tissue Doppler imaging are decreased immediately following ligation and may provide more sensitive markers of LV performance.<sup>33</sup>

The early use of milrinone for infants with low LVO after ligation decreases the need for postoperative inotropic support and the incidence of PLCS from 44% to 11%.<sup>32</sup> Milrinone is a phosphodiesterase III inhibitor with vasodilator, inotropic and lusitropic properties. The pathophysiological contribution to PLCS of increased afterload, impaired LV performance, and diastolic dysfunction makes milrinone a biologically attractive agent.<sup>32</sup> Using bioreactance to continuously monitor cardiac output postligation, milrinone monotherapy for postoperative LVO less than 200 ml/min/kg has been shown to be associated with recovery of LVO.<sup>34</sup> In a retrospective cohort of neonates with low LVO 1-hour postligation, treatment with prophylactic milrinone was associated with improved LVO and tissue Doppler systolic velocities in the lateral and septal wall, with no significant effects on diastolic markers.<sup>31</sup> This suggests that the primary mechanism of action is related to improved systolic function with afterload reduction rather than lusitropy. Concerns related to excessive vasodilation and the impact of preload in the immature myocardium can be minimized with the co-administration of a 10 mL/kg normal saline bolus during the first hour of milrinone infusion.<sup>22,32</sup>

In patients who have not been treated with prophylactic milrinone, effective treatment of established PLCS should focus on inotropic agents such as dobutamine and/or epinephrine according to illness severity (Figure 3). Milrinone initiation is contraindicated



**FIGURE 3** Pathophysiological contributors to cardiorespiratory instability following patent ductus arteriosus ligation and associated clinical implications.<sup>22,31</sup> Abbreviations: BP, blood pressure; CO, cardiac output; GLS, global longitudinal strain; IVRT, isovolumetric relaxation time; LA, left atrium; LVO, left ventricular output; MAP, mean airway pressure; LV, left ventricle; SVR, systemic vascular resistance

once systemic, particularly diastolic, hypotension is established due to its vasodilator properties and consequential potential for severe hypotension and poor coronary perfusion. In addition, the use of vasopressors with little or no support of myocardial performance (eg, dopamine, vasopressin, and norepinephrine) should be avoided as they may worsen the already established effects of increased SVR postductal closure. Hydrocortisone should be considered early in those with severe and/or refractory hypotension, especially in the setting of a preoperative failed ACTH stimulation test.<sup>22</sup> Despite the benefits of milrinone in reducing the incidence of hemodynamic compromise, a subset of patients still develop oxygenation and/or ventilation failure presumably related to diastolic dysfunction and pulmonary edema.<sup>20</sup> In this situation, increases in mean airway pressure, diuretic therapy, and optimization of milrinone therapy for afterload reduction are preferred.<sup>22</sup>

Surgical complications, though infrequent, should be considered in the situation when a neonate becomes sick in the immediate postoperative period. Pneumothorax, hemothorax either related to ductal rupture or injury to intercostal vessels intraoperatively or by chest drain and chylothorax due to thoracic duct disruption should be considered. Early chest radiography in the setting of either oxygenation or cardiovascular concern is recommended. Increased intrathoracic pressure due to these complications may be poorly tolerated and may cause early, severe hypotension.

## 7 | NONINVASIVE CLOSURE—AN ALTERNATIVE TO SURGERY

Transcatheter closure has been reported in neonates as light as 750 g and new techniques have been reported to have reduced morbidity and mortality. Historically, arterial cannulization and device delivery have led to complications such as arterial thrombosis which have restricted use in small patients. Newer transvenous techniques using ultrasound and/or small doses of fluoroscopy have more acceptable risk profiles. Transient obstruction of either left pulmonary artery or aorta and femoral thrombosis have been noted, although are generally manageable with conservative therapy.<sup>35,36</sup> Early reports suggest that postprocedure recovery time<sup>35</sup> and the risk of PLCS is lower following catheter vs surgical closure.<sup>36</sup> Although the number of high-risk patients treated is small thus far, whereas surgical ligation creates an inflammatory cascade which may further augment postoperative afterload, catheter closure may be a less potent inflammatory stimulus thereby reducing the compounding impact on LV performance. Additionally, the absence of lung retraction and swings in intrathoracic pressure associated with thoracotomy may reduce lung injury. Further scientific exploration in this area is needed.

## 8 | CONCLUSION

Ligation of a hemodynamically significant ductus arteriosus results in significant changes in loading conditions which have predictable

consequences. The development of PLCS resultant from LV failure due to the sustained exposure to afterload is a major cause of postoperative hemodynamic instability. LV systolic dysfunction results in poor perfusion requiring inotrope therapy and LV diastolic dysfunction contributes to impaired oxygenation and ventilation. TnECHO guided initiation of milrinone for high-risk patients with low LVO 1-hour after ligation lowers the risk of postoperative decompensation. It is important to recognize, however, that some patients may develop cardiorespiratory instability secondary to surgical complications or impaired adrenal performance. Anticipatory management and decision making based on actual physiology may improve cardiovascular stability during and after surgery.

## CONFLICTS OF INTEREST

The authors declare that they have no conflicts of interest with the contents of this article.

## AUTHORS CONTRIBUTIONS

*Regan E. Giesinger*: Co-authored first draft, edited revisions, and created figures.

*Adrienne R. Bischoff*: Co-authored first draft.

*Patrick J. McNamara*: Designed the project, provided supervision, and edited the manuscript. All authors reviewed and approved the final version.

## ORCID

*Regan E. Giesinger*  <https://orcid.org/0000-0002-6227-6761>

## REFERENCES

1. Lokku A, Mirea L, Lee SK, Shah PS. Trends and outcomes of patent ductus arteriosus treatment in very preterm infants in Canada. *Am J Perinatol*. 2017;34:441-450.
2. Kabra NS, Schmidt B, Roberts RS, Doyle LW, Papile L, Fanaroff A. Neurosensory impairment after surgical closure of patent ductus arteriosus in extremely low birth weight infants: results from the trial of indomethacin prophylaxis in preterms. *J Pediatr*. 2007;150:229-234.
3. Chorne N, Leonard C, Piecuch R, Clyman RI. Patent ductus arteriosus and its treatment as risk factors for neonatal and neurodevelopmental morbidity. *Pediatrics*. 2007;119:1165-1174.
4. Weisz DE, Mirea L, Rosenberg E, et al. Association of patent ductus arteriosus ligation with death or neurodevelopmental impairment among extremely preterm infants. *JAMA Pediatr*. 2017;171:443-449.
5. Moin F, Kennedy KA, Moya FR. Risk factors predicting vasopressor use after patent ductus arteriosus ligation. *Am J Perinatol*. 2003;20:313-320.
6. Harting MT, Blakely ML, Cox CS Jr, Lantin-Hermoso R, Andrassy RJ, Lally KP. Acute hemodynamic decompensation following patent ductus arteriosus ligation in premature infants. *J Invest Surg*. 2008;21:133-138.
7. Clyman RI, Wickremasinghe A, Merritt TA, et al. Hypotension following patent ductus arteriosus ligation: the role of adrenal hormones. *J Pediatr*. 2014;164:1449-1455.e1.

8. Ulrich T, Hansen TP, Reid KJ, Bingler MA, Olsen SL. Post-ligation cardiac syndrome is associated with increased morbidity in preterm infants. *J Perinatol*. 2018;38:537-542.
9. Gerhardt T, Bancalari E. Lung compliance in newborns with patent ductus arteriosus before and after surgical ligation. *Biol Neonate*. 1980;38:96-105.
10. Broadhouse KM, Price AN, Durighel G, et al. Assessment of PDA shunt and systemic blood flow in newborns using cardiac MRI. *NMR Biomed*. 2013;26:1135-1141.
11. Sarkar S, Dechert R, Schumacher RE, Donn SM. Is refractory hypotension in preterm infants a manifestation of early ductal shunting? *J Perinatol*. 2007;27:353-358.
12. Willenbrock R, Stauss H, Scheuermann M, Osterziel KJ, Unger T, Dietz R. Effect of chronic volume overload on baroreflex control of heart rate and sympathetic nerve activity. *Am J Physiol*. 1997;273:H2580-H2585.
13. Reller MD, Morton MJ, Reid DL, Thornburg KL. Fetal lamb ventricles respond differently to filling and arterial pressures and to in utero ventilation. *Pediatr Res*. 1987;22:621-626.
14. Friedman WF. The intrinsic physiologic properties of the developing heart. *Prog Cardiovasc Dis*. 1972;15:87-111.
15. Sheridan DJ, Cullen MJ, Tynan MJ. Qualitative and quantitative observations on ultrastructural changes during postnatal development in the cat myocardium. *J Mol Cell Cardiol*. 1979;11:1173-1181.
16. Smolich JJ, Walker AM, Campbell GR, Adamson TM. Left and right ventricular myocardial morphometry in fetal, neonatal, and adult sheep. *Am J Physiol*. 1989;257:H1-H9.
17. McNamara PJ, Stewart L, Shivananda SP, Stephens D, Sehgal A. Patent ductus arteriosus ligation is associated with impaired left ventricular systolic performance in premature infants weighing less than 1000 g. *J Thorac Cardiovasc Surg*. 2010;140:150-157.
18. Taylor AF, Morrow WR, Lally KP, Kinsella JP, Gerstmann DR, deLemos RA. Left ventricular dysfunction following ligation of the ductus arteriosus in the preterm baboon. *J Surg Res*. 1990;48:590-596.
19. Teixeira LS, Shivananda SP, Stephens D, Van Arsdell G, McNamara PJ. Postoperative cardiorespiratory instability following ligation of the preterm ductus arteriosus is related to early need for intervention. *J Perinatol*. 2008;28:803-810.
20. Ting JY, Resende M, More K, et al. Predictors of respiratory instability in neonates undergoing patent ductus arteriosus ligation after the introduction of targeted milrinone treatment. *J Thorac Cardiovasc Surg*. 2016;152:498-504.
21. Ibrahim MH, Azab A, Kamal NM, et al. Outcomes of early ligation of patent ductus arteriosus in preterms, multicenter experience. *Medicine*. 2015;94:e915.
22. Weisz DE, Giesinger RE. Surgical management of a patent ductus arteriosus: Is this still an option? *Semin Fetal Neonatal Med*. 2018;23:255-266.
23. De Buyst J, Rakza T, Pennaforte T, Johansson AB, Storme L. Hemodynamic effects of fluid restriction in preterm infants with significant patent ductus arteriosus. *J Pediatr*. 2012;161:404-408.
24. Lemyre B, Liu L, Moore GP, Lawrence SL, Barrowman NJ. Do intraoperative fluids influence the need for post-operative cardiotropic support after a PDA ligation? *Zhongguo dang dai er ke za zhi [Chin J Contemp Pediatr]*. 2011;13:1-7.
25. Noonan M, Turek JW, Dagle JM, McElroy SJ. Intraoperative High-frequency jet ventilation is equivalent to conventional ventilation during patent ductus arteriosus ligation. *World J Pediatr Congenit Heart Surg*. 2017;8:570-574.
26. El-Khuffash A, McNamara PJ, Lapointe A, Jain A. Adrenal function in preterm infants undergoing patent ductus arteriosus ligation. *Neonatology*. 2013;104:28-33.
27. Quintos JB, Boney CM. Transient adrenal insufficiency in the premature newborn. *Curr Opin Endocrinol Diabetes Obes*. 2010;17:8-12.
28. Fernandez EF, Montman R, Watterberg KL. Adrenal function in newborns undergoing surgery. *J Perinatol*. 2010;30:814-818.
29. Satpute MD, Donohue PK, Vricella L, Aucott SW. Cardiovascular instability after patent ductus arteriosus ligation in preterm infants: the role of hydrocortisone. *J Perinatol*. 2012;32:685-689.
30. Kimball TR, Ralston MA, Khoury P, Crump RG, Cho FS, Reuter JH. Effect of ligation of patent ductus arteriosus on left ventricular performance and its determinants in premature neonates. *J Am Coll Cardiol*. 1996;27:193-197.
31. El-Khuffash AF, Jain A, Weisz D, Mertens L, McNamara PJ. Assessment and treatment of post patent ductus arteriosus ligation syndrome. *J Pediatr*. 2014;165:46-52.e1.
32. Jain A, Sahni M, El-Khuffash A, Khadawardi E, Sehgal A, McNamara PJ. Use of targeted neonatal echocardiography to prevent postoperative cardiorespiratory instability after patent ductus arteriosus ligation. *J Pediatr*. 2012;160:584-589.e1.
33. El-Khuffash AF, Jain A, Dragulescu A, McNamara PJ, Mertens L. Acute changes in myocardial systolic function in preterm infants undergoing patent ductus arteriosus ligation: a tissue Doppler and myocardial deformation study. *J Am Soc Echocardiogr*. 2012;25:1058-1067.
34. Weisz DE, Jain A, Ting J, McNamara PJ, El-Khuffash A. Non-invasive cardiac output monitoring in preterm infants undergoing patent ductus arteriosus ligation: a comparison with echocardiography. *Neonatology*. 2014;106:330-336.
35. Abu Hazeem AA, Gillespie MJ, Thun H, et al. Percutaneous closure of patent ductus arteriosus in small infants with significant lung disease may offer faster recovery of respiratory function when compared to surgical ligation. *Catheter Cardiovasc Interv*. 2013;82:526-533.
36. Zahn EM, Peck D, Phillips A, et al. Transcatheter closure of patent ductus arteriosus in extremely premature newborns: early results and midterm follow-up. *JACC Cardiovasc Interv*. 2016;9:2429-2437.

**How to cite this article:** Giesinger RE, Bischoff AR, McNamara PJ. Anticipatory perioperative management for patent ductus arteriosus surgery: Understanding postligation cardiac syndrome. *Congenital Heart Disease*. 2019;14:311-316. <https://doi.org/10.1111/chd.12738>